

Pocket Guide to POCUS: Point-of-Care Tips for Point-of-Care Ultrasound >

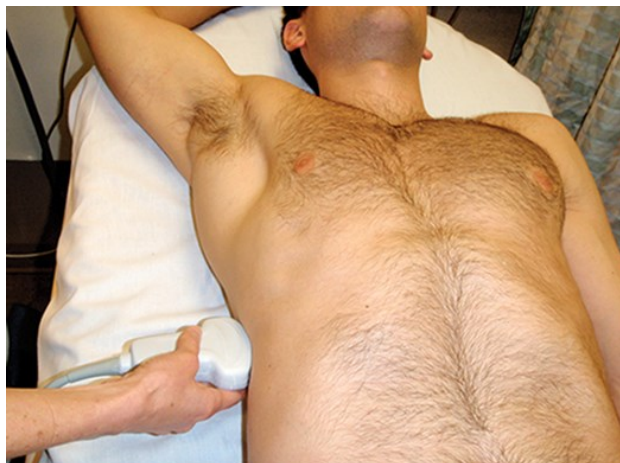Chapter 4: Focused Assessment for Free Fluid (FAFF)

KEY IMAGES

Right upper quadrant

1. Pleural space
2. Subphrenic space
3. Morison's pouch
4. Inferior pole of right kidney and liver

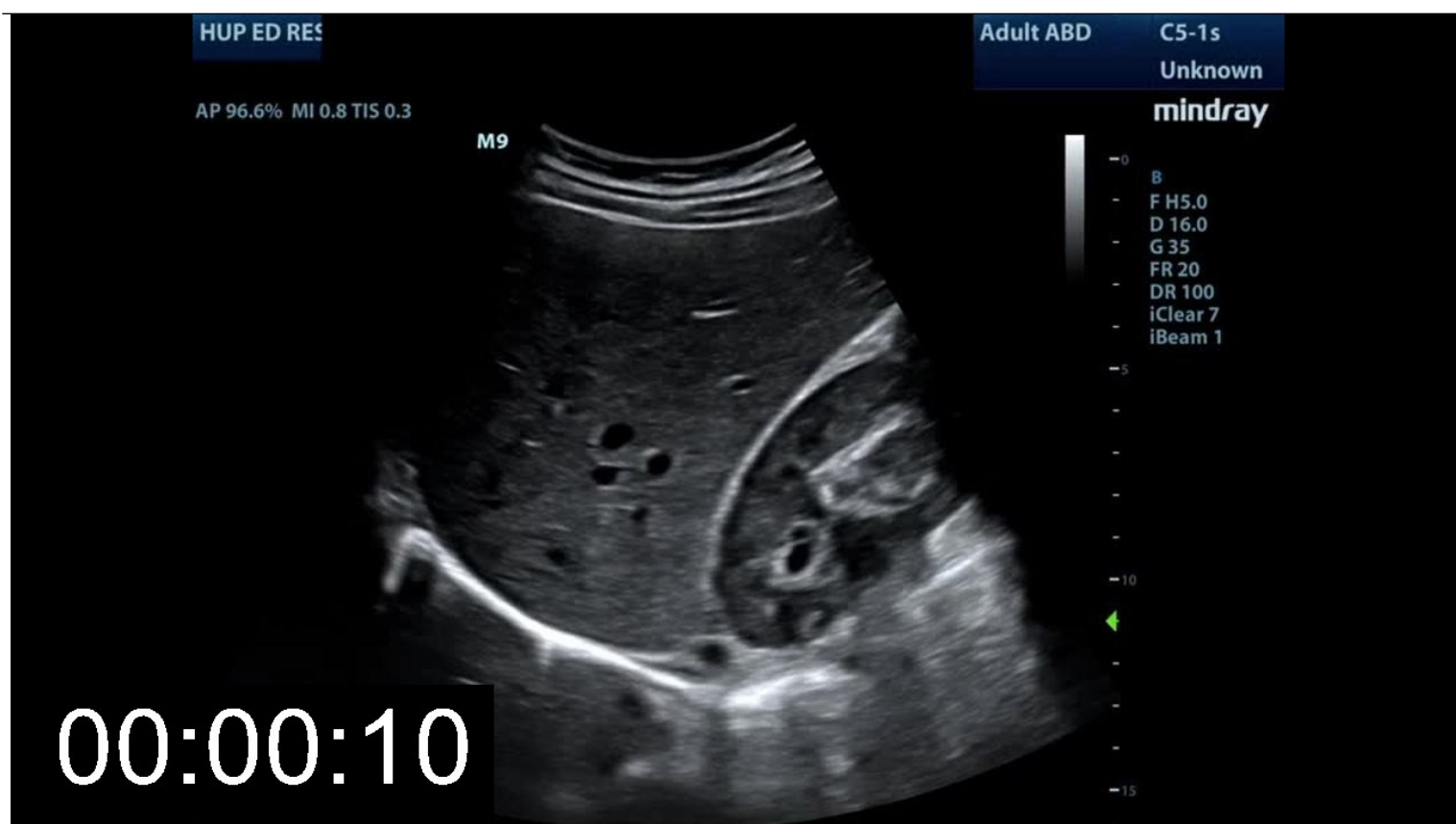Figure 4-1



Source: C. M. Baston, C. Moore, E. A. Krebs, A. J. Dean, N. Panebianco:
Pocket Guide to POCUS: Point-of-Care Tips for Point-of-Care Ultrasound, 1st edition.
Copyright © McGraw-Hill Education. All rights reserved.

Video 04-01: Normal RUQ

This video of a normal right upper quadrant clearly shows all four of the spaces visible in this window. The pleural space has no fluid, as is demonstrated by the mirror artifact in the bottom left corner of the screen, showing a reflection of the liver on the other side of the diaphragm. The hepatorenal recess is a white line without any breaks or fluid collections. The inferior pole of the kidney is incompletely visualized, but is clear. The subdiaphragmatic space is similarly a tight border between liver and diaphragm without anechoic space.

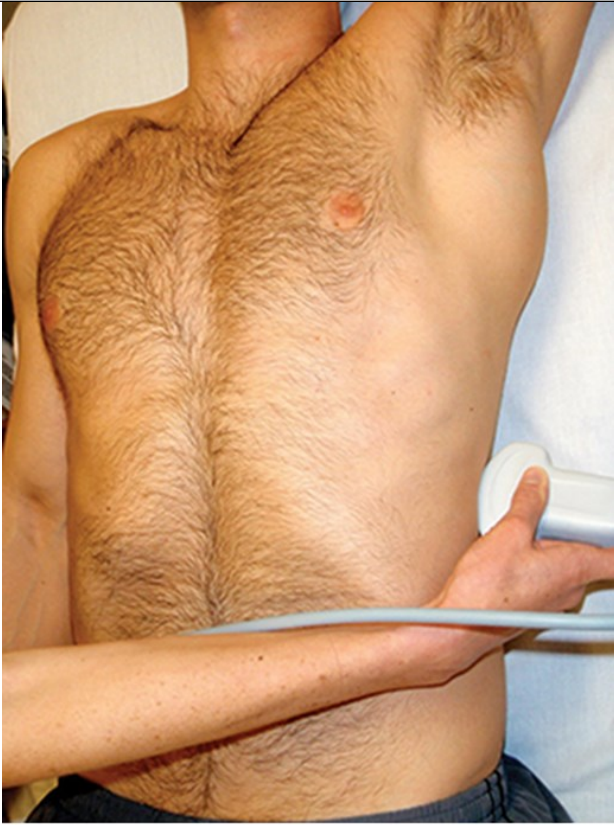

[Play Video](#)

Left upper quadrant

1. Pleural space
2. Subphrenic space
3. Splenorenal recess
4. Inferior pole of left kidney and spleen

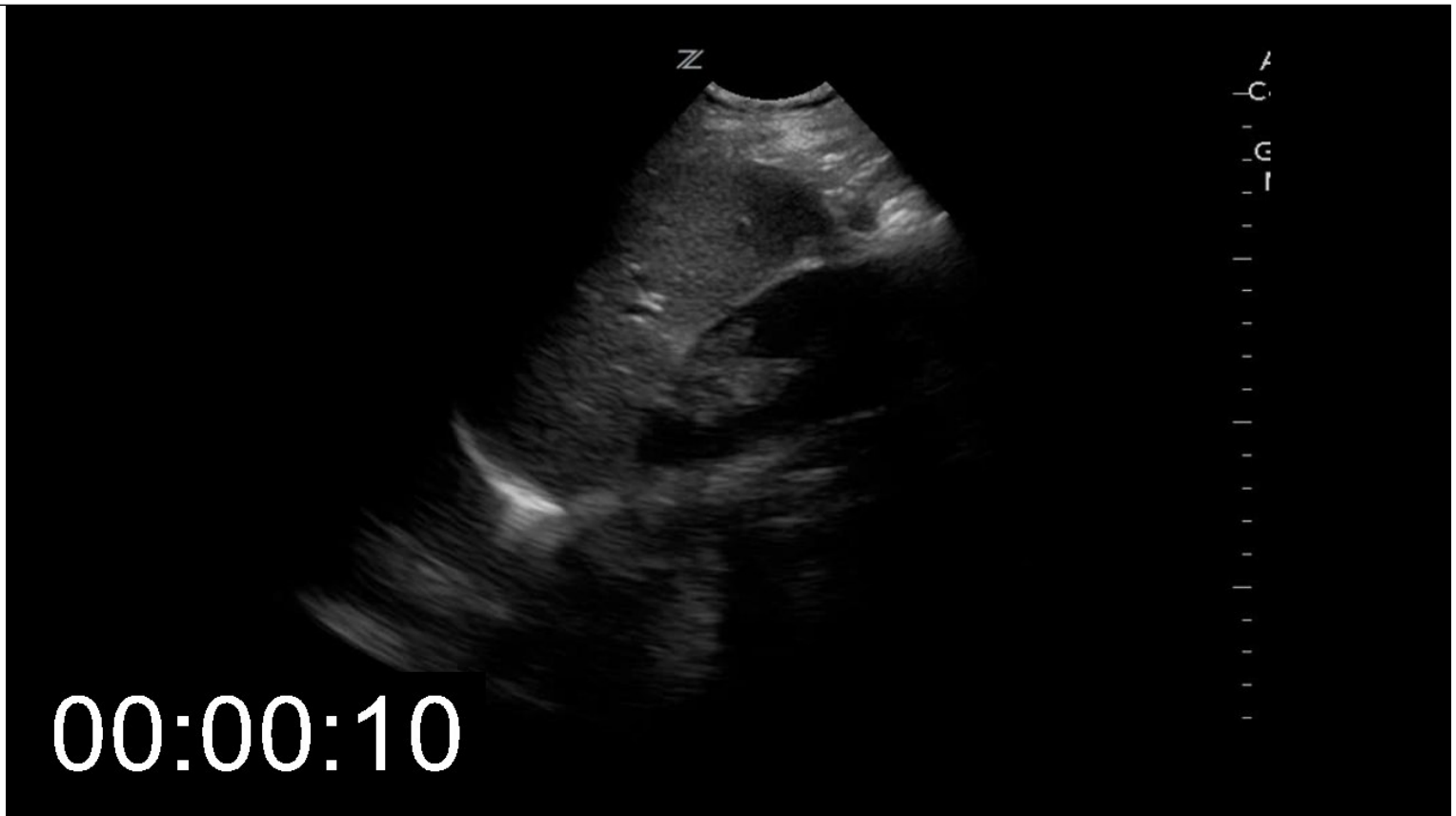
Figure 4-2



Source: C. M. Baston, C. Moore, E. A. Krebs, A. J. Dean, N. Panebianco:
Pocket Guide to POCUS: Point-of-Care Tips for Point-of-Care Ultrasound, 1st edition.
Copyright © McGraw-Hill Education. All rights reserved.

Video 04-02: Normal LUQ

This video of a normal left upper quadrant clearly shows all four of the spaces visible in this window. The pleural space has no fluid, as is demonstrated by the mirror artifact in the bottom left corner of the screen, showing a reflection of the spleen on the other side of the diaphragm. The border between spleen and kidney is similarly without anechoic fluid. The inferior pole of the kidney and spleen are completely visualized, and are clear. The subdiaphragmatic space is similarly a tight border between spleen and diaphragm without anechoic space.

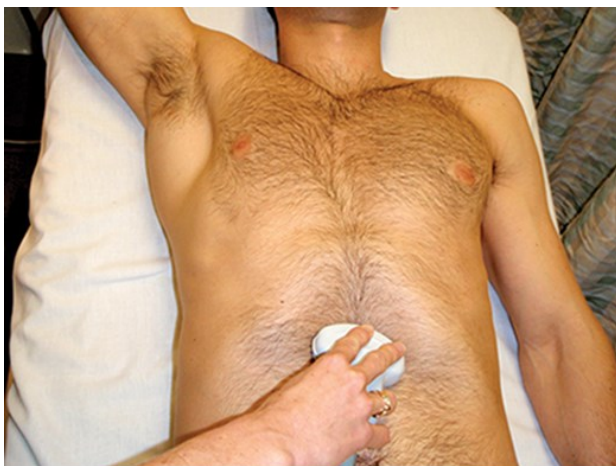

[Play Video](#)

Cardiac

1. Pericardial space

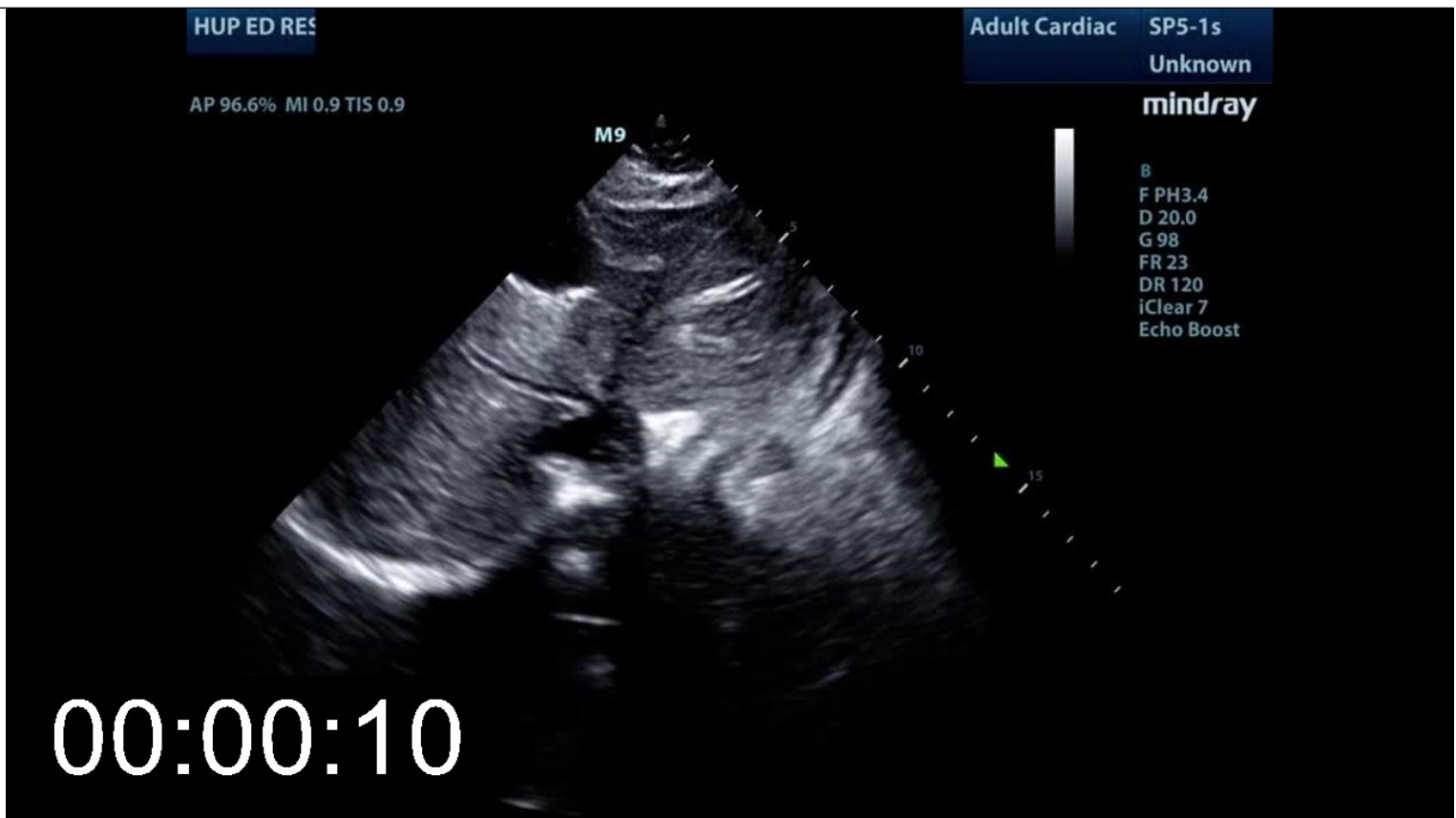
Figure 4-3



Source: C. M. Baston, C. Moore, E. A. Krebs, A. J. Dean, N. Panebianco:
Pocket Guide to POCUS: Point-of-Care Tips for Point-of-Care Ultrasound, 1st edition.
Copyright © McGraw-Hill Education. All rights reserved.

Video 04-03: Normal Subxiphoid

This video demonstrates a subxiphoid view of the heart. The liver is clearly seen in the superficial portion of the video. The bright pericardium can be seen both anteriorly and posteriorly without separations, ruling out pericardial effusion. The operator fans inferiorly to see the right atrium join the IVC. Also in this video a mirror artifact in the bottom left of the screen rules out a right sided pleural effusion.

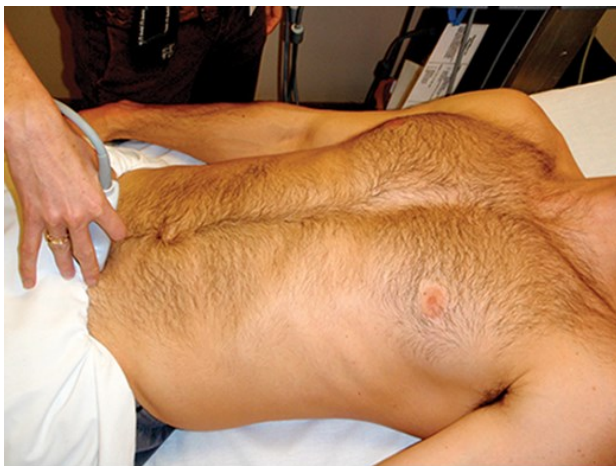

[Play Video](#)

Pelvic

1. Pouch of Douglas (at level of the cervix) or rectovesicular pouch (superior to seminal vesicles)

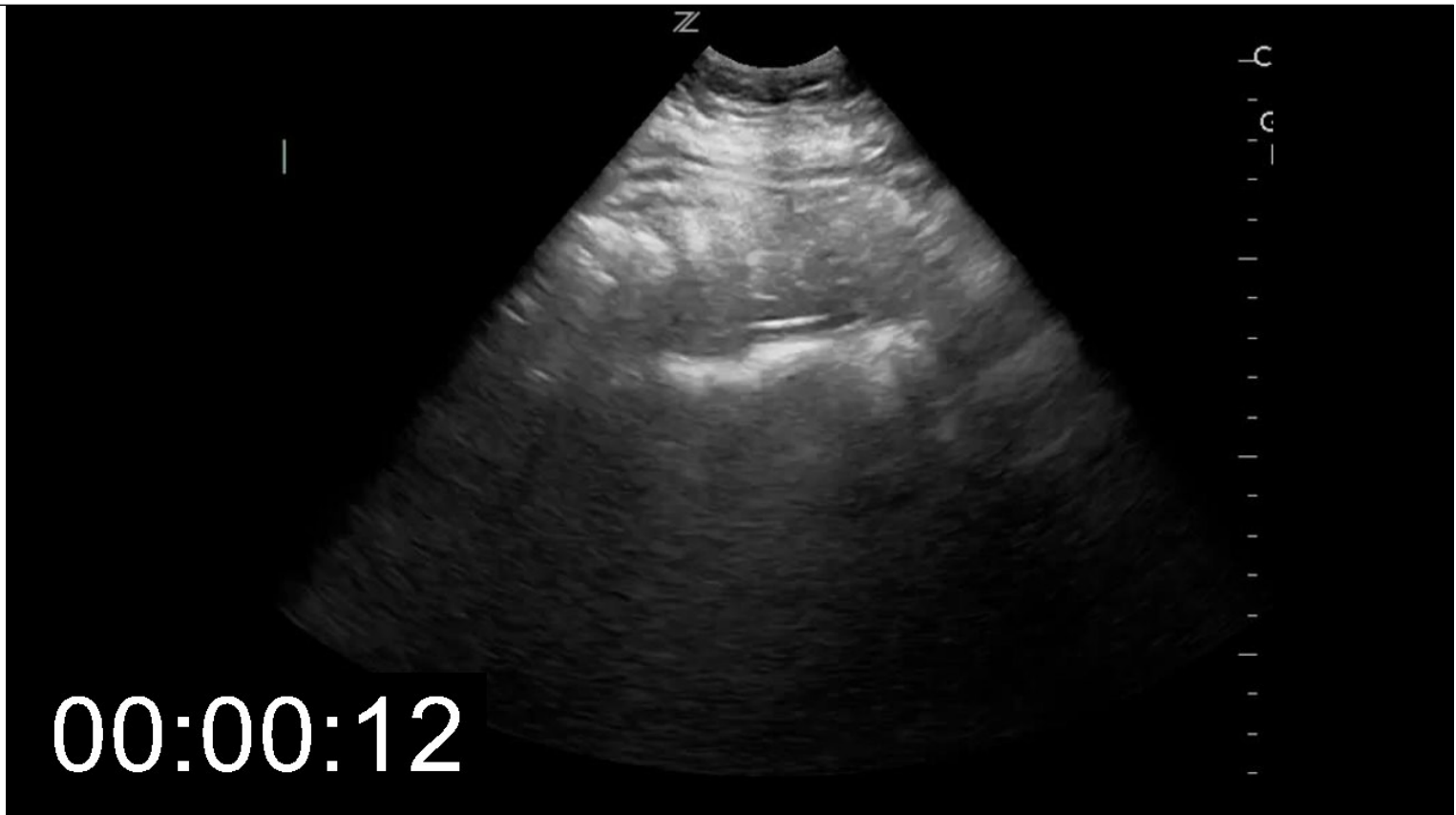
Figure 4-4



Source: C. M. Baston, C. Moore, E. A. Krebs, A. J. Dean, N. Panebianco:
Pocket Guide to POCUS: Point-of-Care Tips for Point-of-Care Ultrasound, 1st edition.
Copyright © McGraw-Hill Education. All rights reserved.

Video 04-04: Normal Pelvic

With the probe placed in the suprapubic position and the indicator to the patient's right, the operator fans inferiorly until the rounded edges of the bladder can be seen. The posterior acoustic enhancement in this case has been mitigated by the time-gain-compensation on the machine, so the prostate and seminal vesicles are also visible, which can sometimes be mistaken for a small amount of free fluid.



[Play Video](#)

ACQUISITION TIPS

- Indications: Hemodynamic instability, peritonitis, concern for thoracoabdominal free fluid, sepsis of unknown source.
- Probe: sector/phased-array or curvilinear (low frequency).
- Lateral decubitus or Trendelenburg positioning enhances evaluation of upper abdominal spaces.
- Decrease far-field gain to correct for posterior acoustic enhancement.
- There are 4 standard windows with a total of 10 potential spaces that need to be evaluated in a complete FAFF exam.

Subxiphoid (SX)

- Probe placed in the epigastrium just inferior to the xiphoid process.
- Probe marker at 9 o'clock.
- Lay the probe nearly flat against the abdomen.
- Apply downward pressure to image below the sternum.
- Have the patient "Take a deep breath and hold."
- See the cardiac chapter for further details.

Right Upper Quadrant (RUQ)

- Place the probe along the midaxillary line at the level of the epigastrium.
- Start with indicator toward the head (12 o'clock), then align the probe parallel with the ribs to maximize visualization.
- Fan the probe anterior to posterior to evaluate the quadrant, sliding up to visualize the pleural space and down to visualize the tip of the liver and kidney.

Left Upper Quadrant (LUQ)

Downloaded 2023-5-8 4:7 P Your IP is 170.232.227.221

Chapter 4: Focused Assessment for Free Fluid (FAFF),

©2023 McGraw Hill. All Rights Reserved. [Terms of Use](#) • [Privacy Policy](#) • [Notice](#) • [Accessibility](#)

- Probe placed along the posterior-axillary line at the level of the epigastrium, the left kidney/spleen are more posterior and superior than the right.
- If having trouble while scanning a supine patient, hold the transducer with the knuckles of the scanning hand against the bed.
- Start with indicator toward the head (12 o'clock), then align the probe parallel with the ribs to maximize visualization.
- Fan the probe anterior to posterior to evaluate the quadrant, sliding up to visualize pleural space and down to visualize tip of the spleen and kidney.

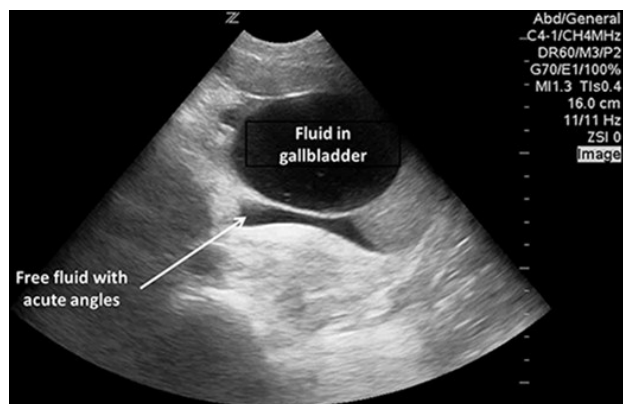
Suprapubic (SP)

- Start by placing the probe immediately superior to pubic symphysis.
- Probe indicator at 9 o'clock for transverse and 12 o'clock for longitudinal.
- Fan inferior to superior and right to left for complete interrogation of the entire pelvis.

INTERPRETATION AND PITFALLS

- Free fluid is pointed and has acute angles. Fluid within organs has rounded edges. This is the most common reason for false positive exams.
- Free fluid in any of the 10 spaces constitutes a positive examination, although trace free fluid in the female pelvis may be physiological.
- The stomach, gallbladder, seminal vesicles, loops of bowel, or other cystic structures can mimic free fluid.
- While the hepatorenal recess (Morison's pouch) tends to be the most sensitive site in the abdomen, fluid may be anywhere, particularly if the patient was sitting or standing before the exam.
- The male pelvis and female pelvis have different anatomy, so fluid will appear in different anatomic locations.
- Perinephric fat can be mistaken for free fluid, but it should be bilateral, unchanging with positioning, and consistent with patient habitus.
- If the vagina is visible in the pelvic view, the probe is aimed too inferiorly.
- If bowel is obstructing the view, firm persistent pressure may help.
- Pneumoperitoneum or subcutaneous emphysema will complicate your exam and limit your views. Consider this diagnosis if all views are unobtainable.
- Mirror artifact of the liver on the superior side of the diaphragm is a normal finding in the RUQ and is lost with the presence of fluid in the pleural space.
- Typically 200 to 600 cc of fluid is required for a positive exam. Consider repeat exams if clinically indicated.
- FAFF is not sensitive for detecting solid organ injury, retroperitoneal bleeding, mesenteric vascular injuries, or hollow viscus injuries.
- Clotted blood may be missed, as it has an appearance similar to that of soft tissue.

Figure 4-5

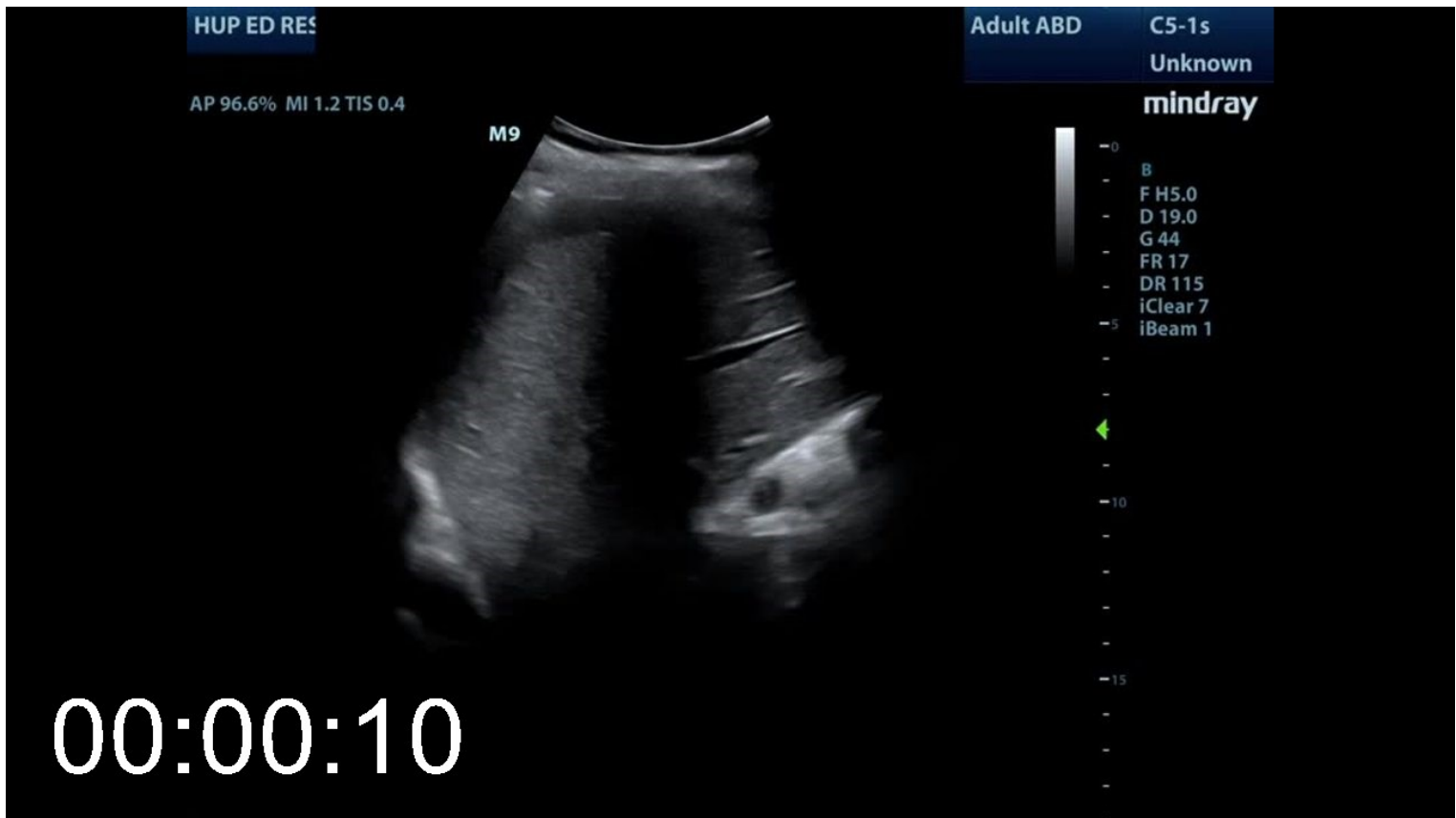


Source: C. M. Baston, C. Moore, E. A. Krebs, A. J. Dean, N. Panebianco:
Pocket Guide to POCUS: Point-of-Care Tips for Point-of-Care Ultrasound, 1st edition.
Copyright © McGraw-Hill Education. All rights reserved.

EXAMPLES OF PATHOLOGY

Video 04-05: Abnormal RUQ

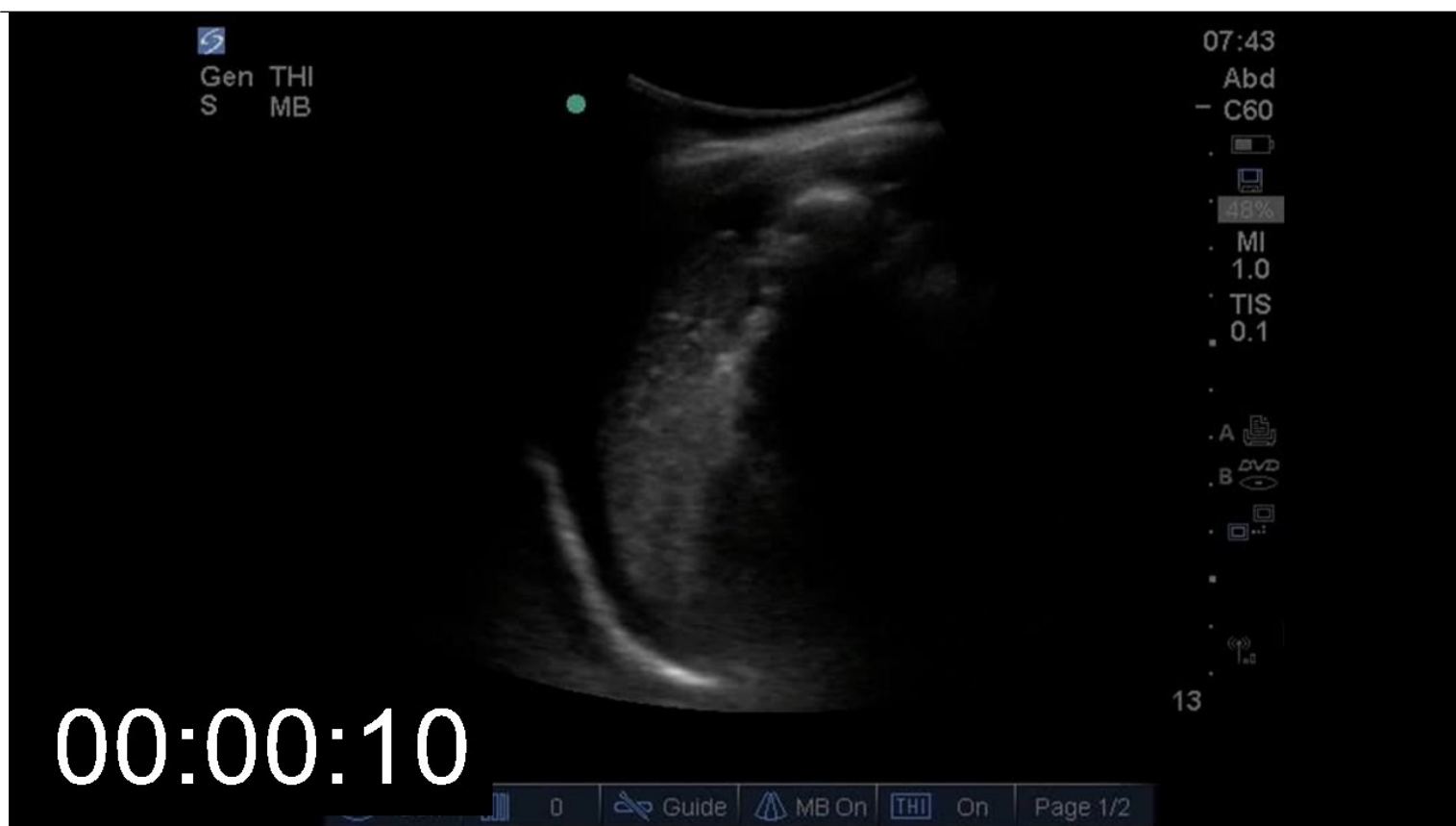This video is taken in the right upper quadrant. The rib shadows move across the field, temporarily obscuring views of the relevant spaces. In between the shadows, however, is an anechoic space in the hepatorenal recess (also known as Morrison's pouch). There is also an absence of mirror artifact in the pleural space, suggesting a right sided pleural effusion.



[Play Video](#)

Video 04-06: Abnormal LUQ

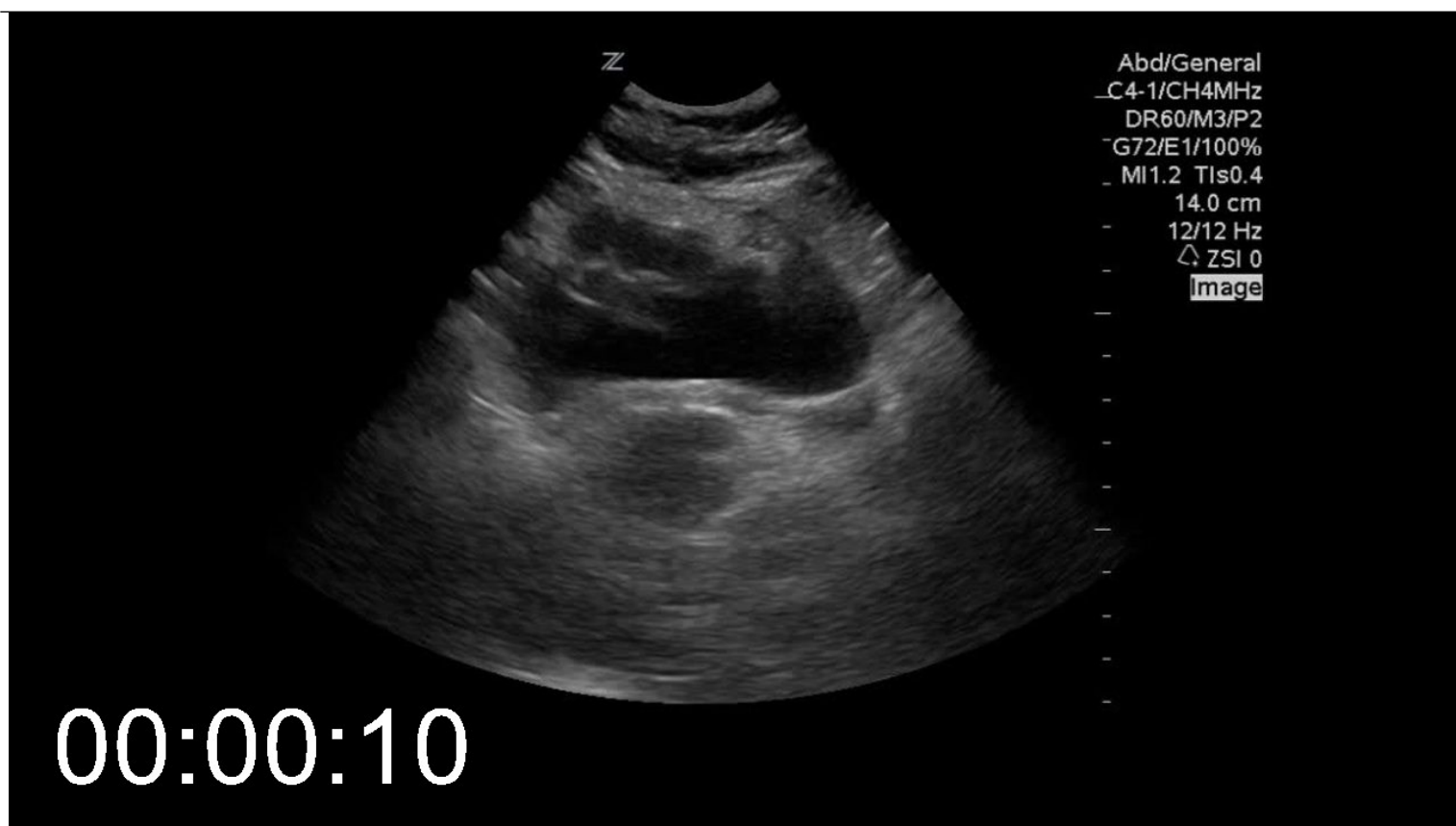This LUQ view shows fluid in the subdiaphragmatic space. The spleen is visible floating in and out of plane. The stomach is on the right side of the screen demonstrating air artifact with shadows. The pleural space does not have fluid in this video, but is instead demonstrating a mirror artifact of the fluid in the subdiaphragmatic space.



[Play Video](#)

Video 04-07: Abnormal Pelvic - Female

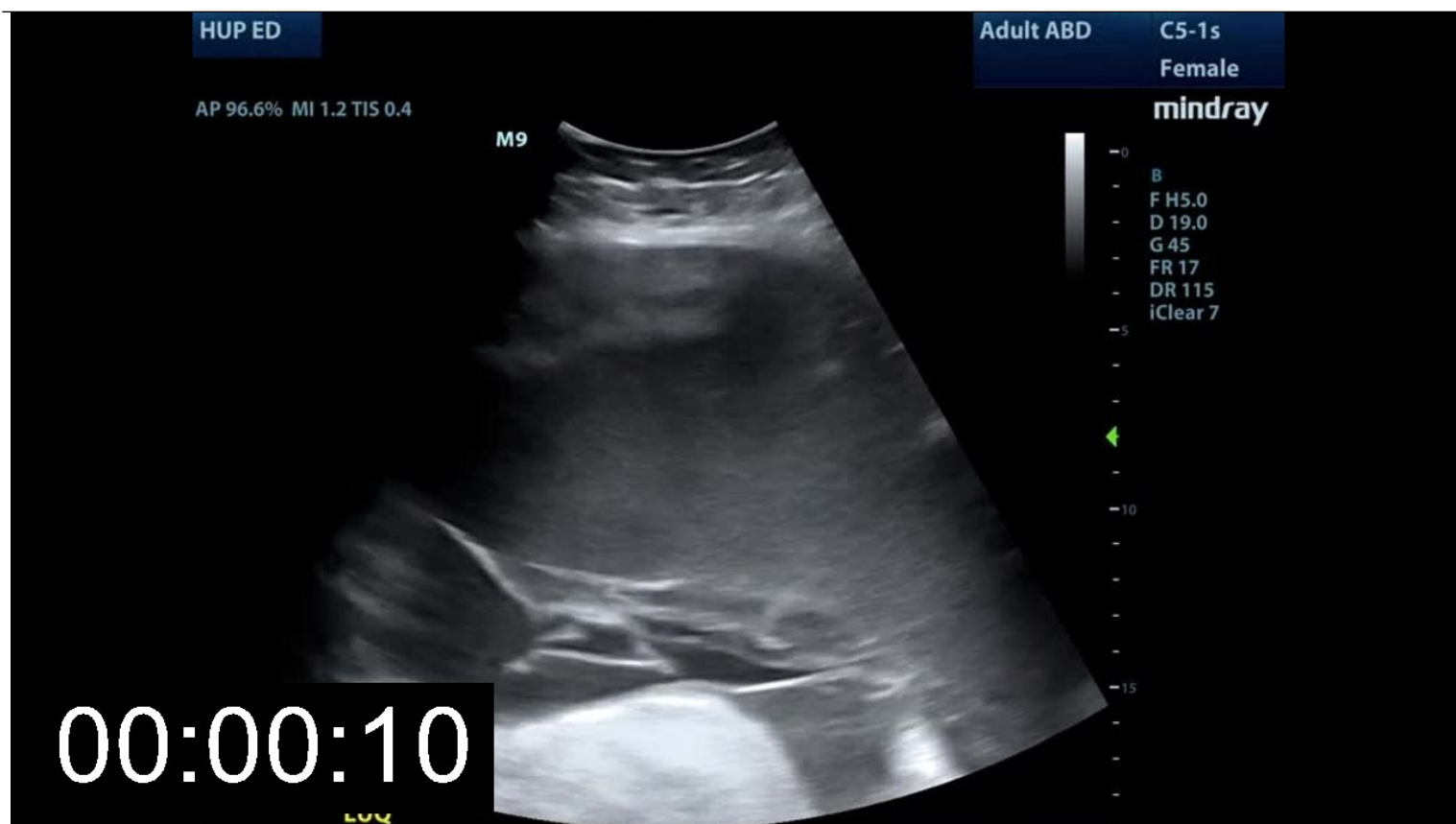This view demonstrates a bladder with a normal amount of urine. On the sides, however, anechoic fluid with pointed acute angles can be seen outside the rounded edges of the bladder. As the operator fans superiorly, fluid can be seen around the uterus (in the pouch of Douglass) and around several loops of bowel.



[Play Video](#)

Video 04-08: Loculated Ascites

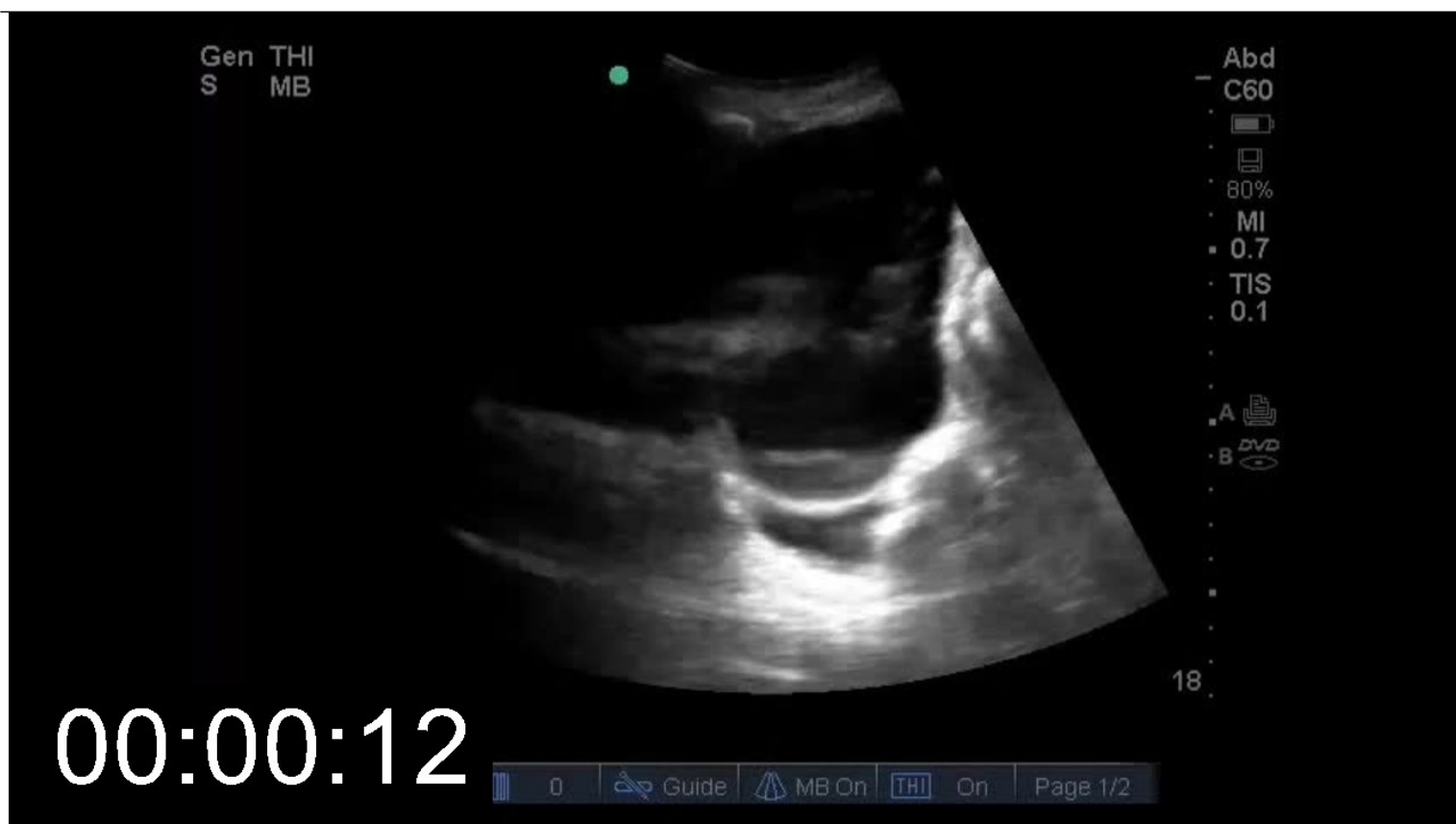This video demonstrates anechoic fluid deep to the spleen, but with thin echoic septations traversing the space, suggesting a complex etiology.



[Play Video](#)

Video 04-09: Abnormal Pelvic - Male

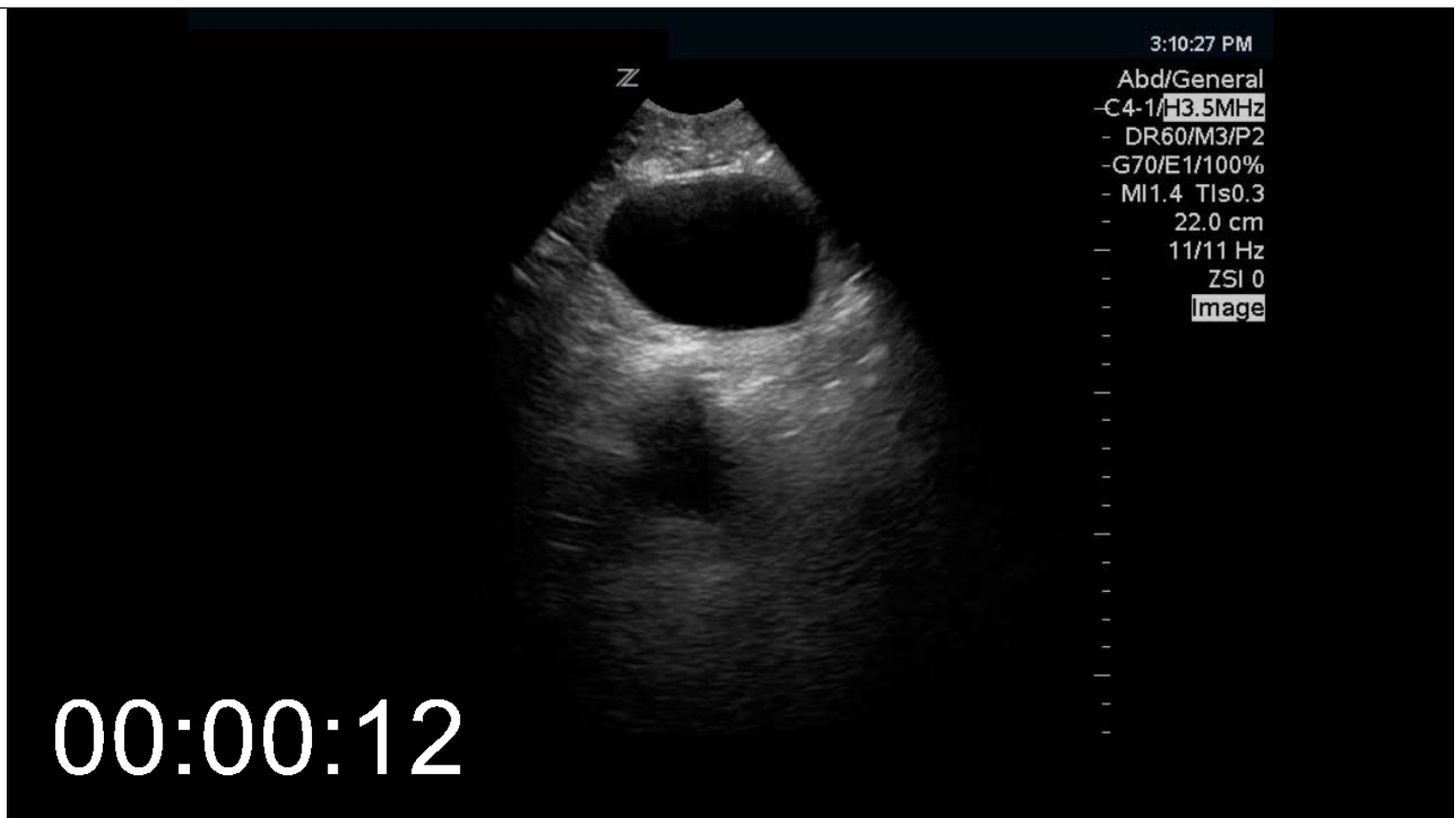
This video shows a full bladder with free fluid visible deep to the bladder. If the gain were set too high, the posterior acoustic enhancement might hide this finding.



[Play Video](#)

Video 04-10: Seminal Vesicles

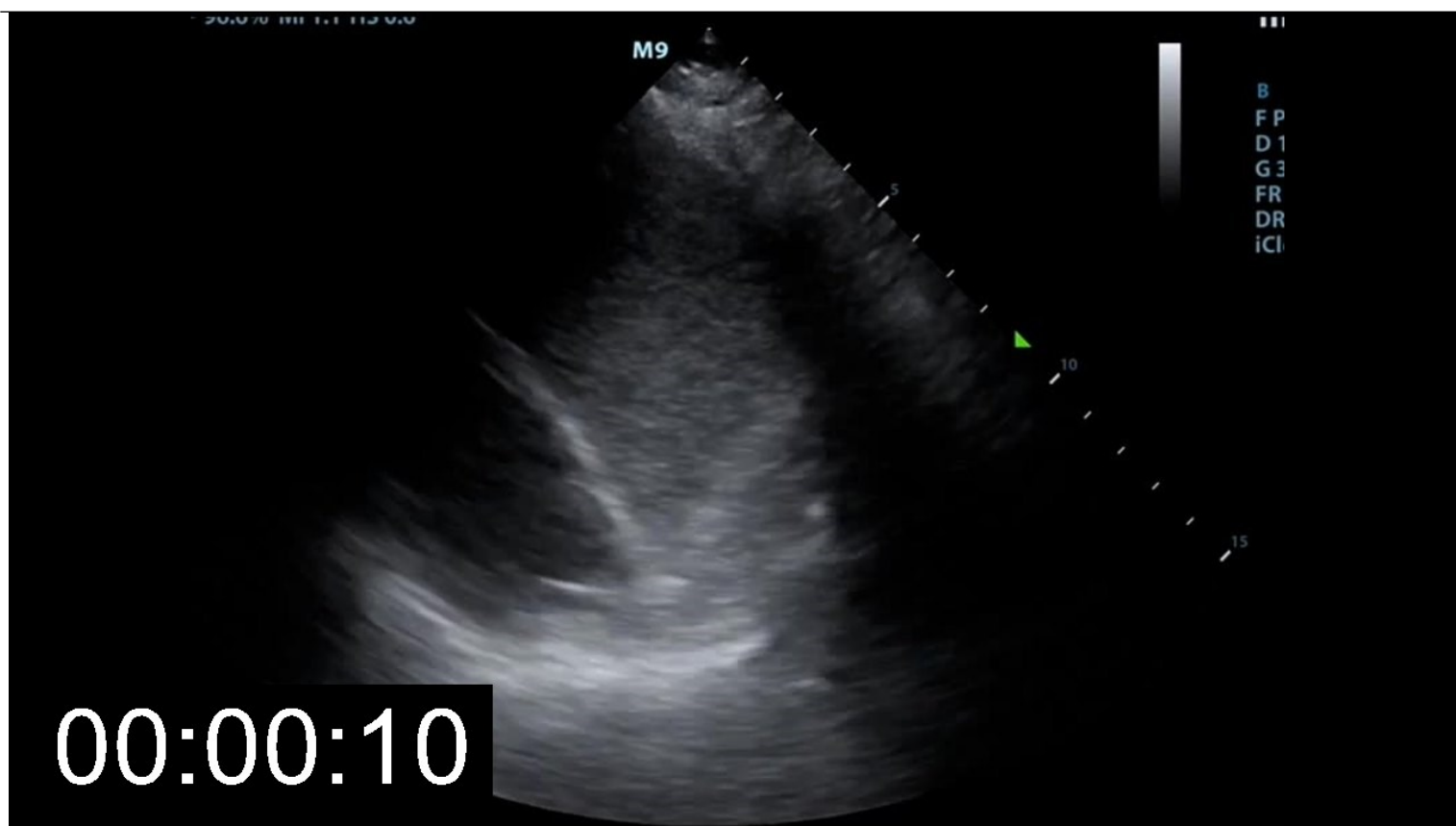This video shows a very quick scan through a male pelvis. If not careful, one could mistake the seminal vesicles seen deep to the bladder for a thin line of free fluid.



[Play Video](#)

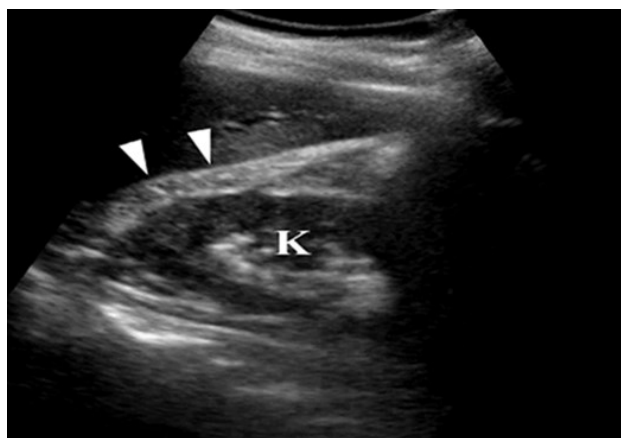Video 04-11: LUQ Fluid Filled Stomach

This video shows a fluid filled structure next to the spleen in the left upper quadrant. This is a fluid filled stomach, and the anatomic location, rounded edges, and rugae can be used to distinguish this from free fluid in the abdomen.



[Play Video](#)

Figure 4-6



Source: C. M. Baston, C. Moore, E. A. Krebs, A. J. Dean, N. Panebianco:
Pocket Guide to POCUS: Point-of-Care Tips for Point-of-Care Ultrasound, 1st edition.
Copyright © McGraw-Hill Education. All rights reserved.