

Pocket Guide to POCUS: Point-of-Care Tips for Point-of-Care Ultrasound >

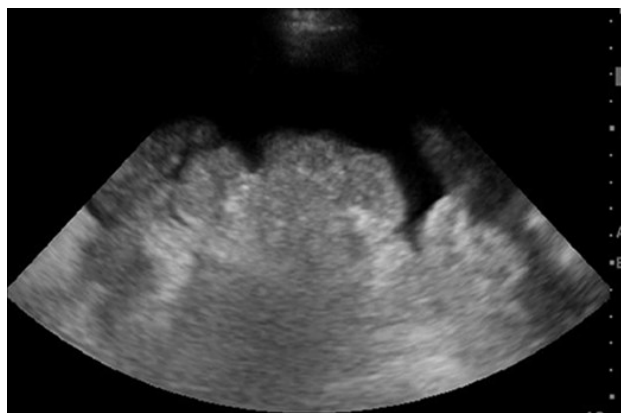## Chapter 5: Ultrasound-Guided Paracentesis

### KEY IMAGES

#### Left lower quadrant (LLQ)

Orient probe longitudinally, and fan

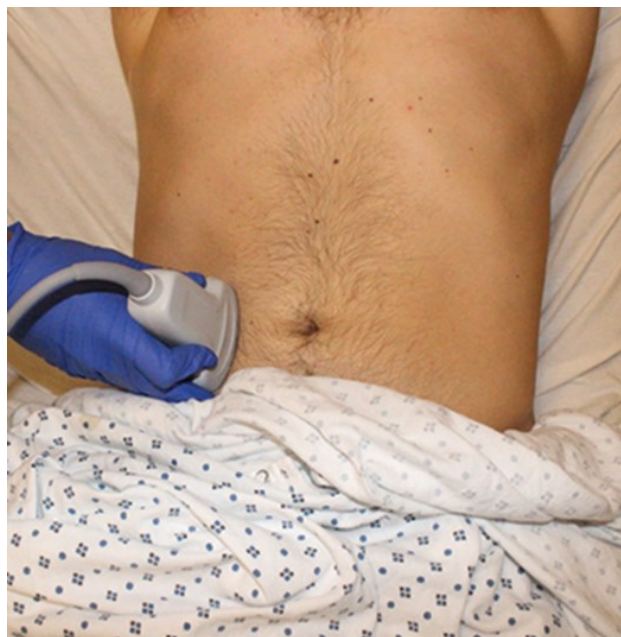Figure 5-1



Source: C. M. Baston, C. Moore, E. A. Krebs, A. J. Dean, N. Panebianco:  
*Pocket Guide to POCUS: Point-of-Care Tips for Point-of-Care Ultrasound*, 1st edition.  
Copyright © McGraw-Hill Education. All rights reserved.

#### Hand position for left lower quadrant

Figure 5-2



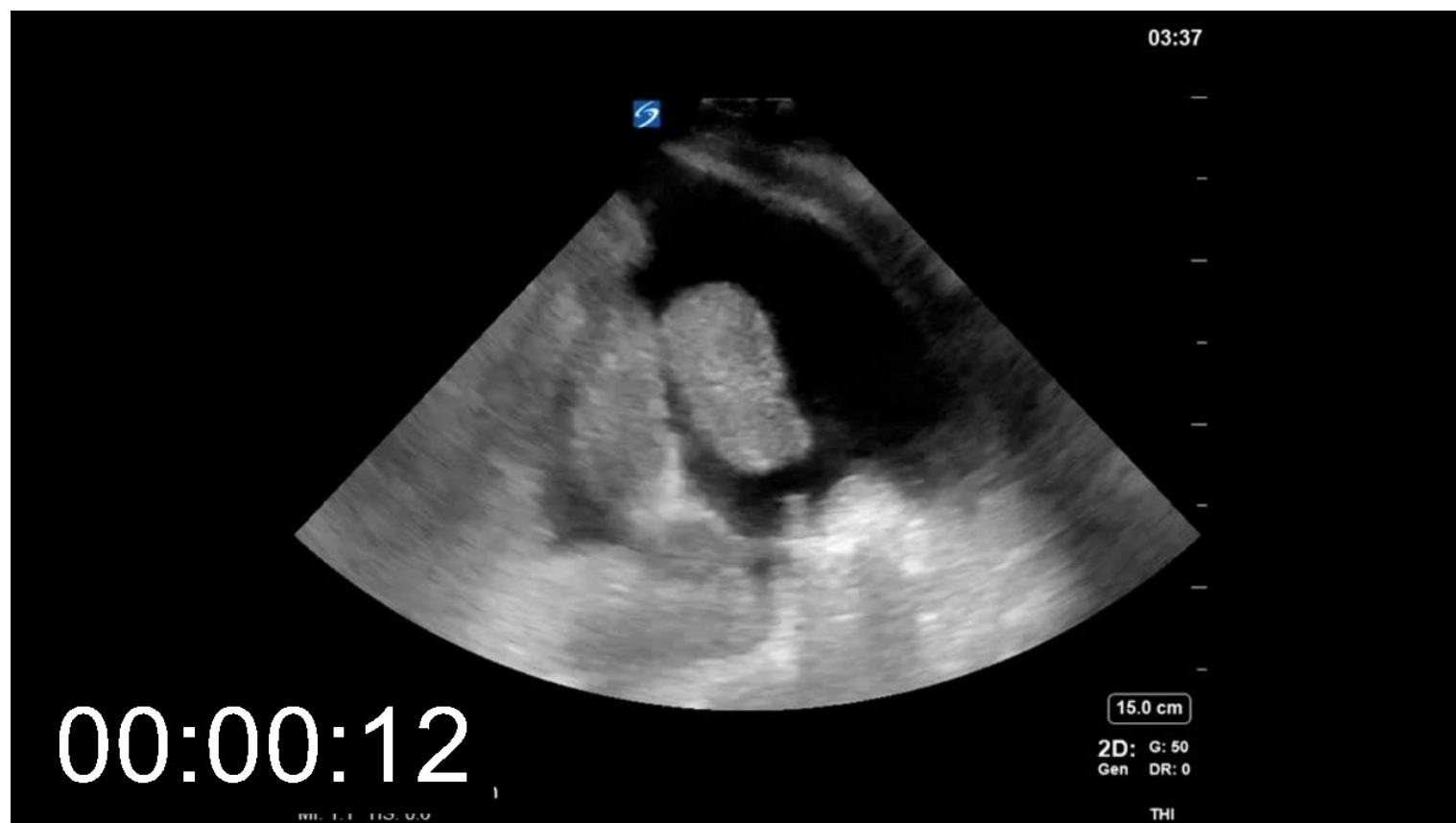Source: C. M. Baston, C. Moore, E. A. Krebs, A. J. Dean, N. Panebianco:  
*Pocket Guide to POCUS: Point-of-Care Tips for Point-of-Care Ultrasound*, 1st edition.  
Copyright © McGraw-Hill Education. All rights reserved.

#### Right lower quadrant (RLQ)

Orient probe longitudinally, and fan

Video 05-01: Free fluid in right lower quadrant

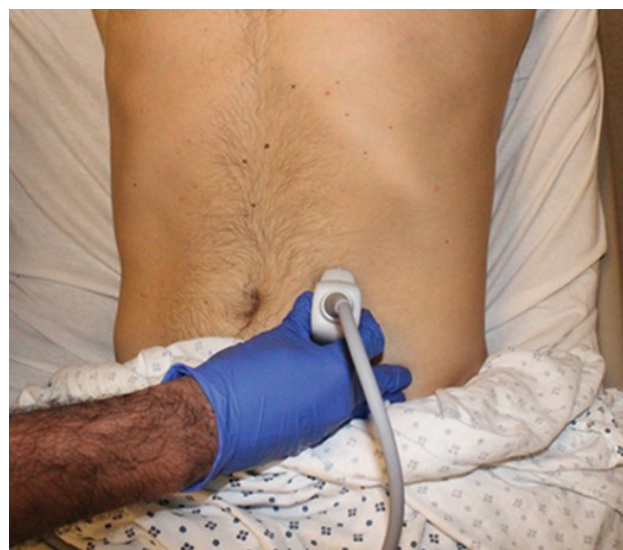Free fluid and bowel can be seen in the RLQ of this video. Fanning through the fluid demonstrates the presence of bowel loops that were just out of the plane of view. While this is potentially accessible, it is preferable to access a space without bowel in the potential needle path.



[Play Video](#)

Hand position for right lower quadrant

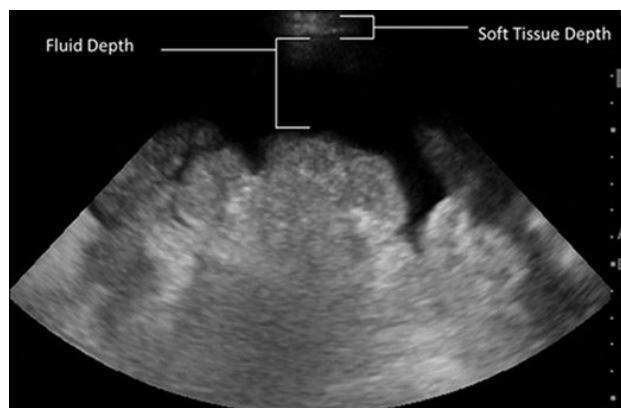
Figure 5-3



Source: C. M. Baston, C. Moore, E. A. Krebs, A. J. Dean, N. Panebianco:  
Pocket Guide to POCUS: Point-of-Care Tips for Point-of-Care Ultrasound, 1st edition.  
Copyright © McGraw-Hill Education. All rights reserved.

## Still image of measurements

Figure 5-4

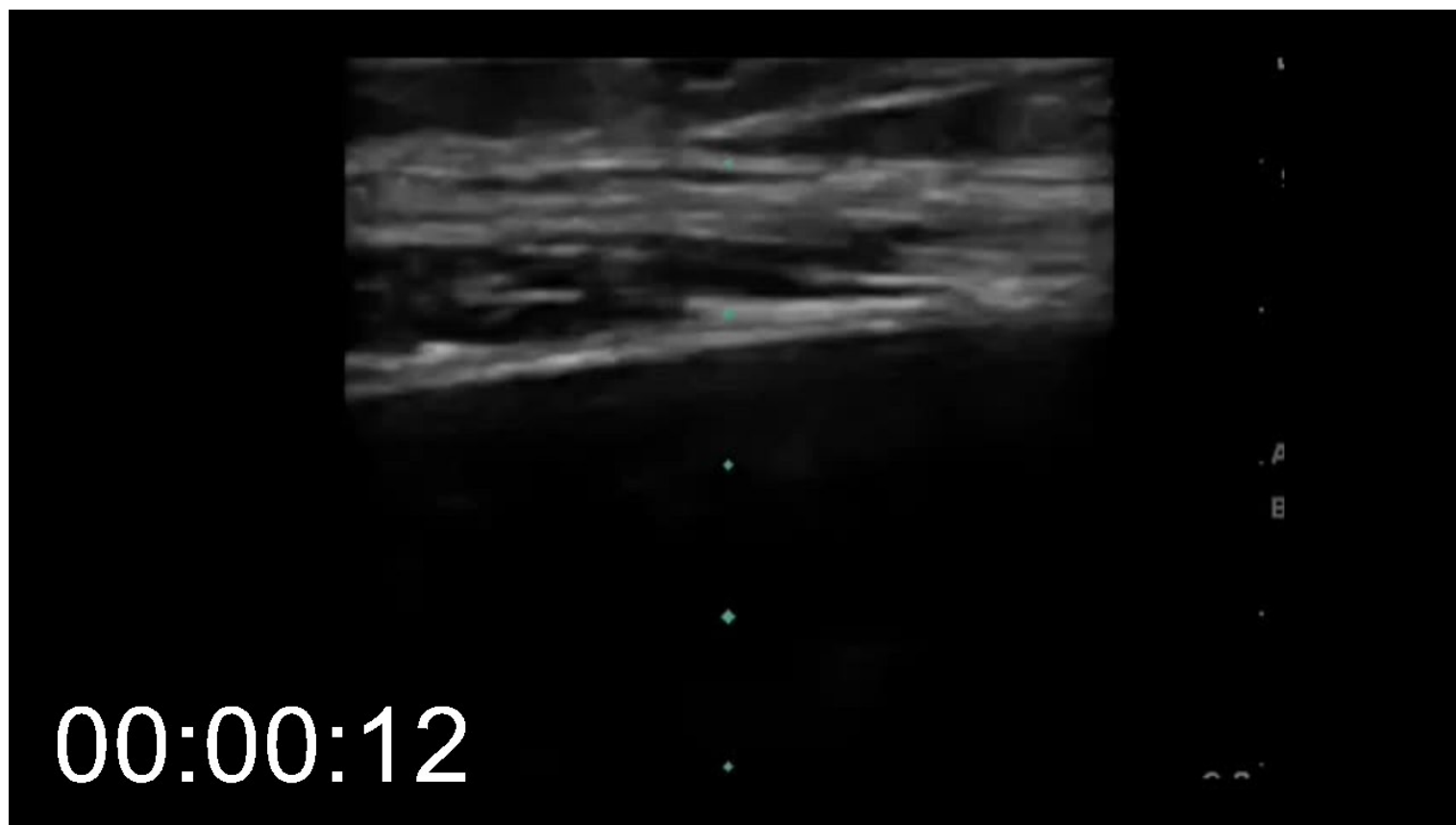


Source: C. M. Baston, C. Moore, E. A. Krebs, A. J. Dean, N. Panebianco:  
*Pocket Guide to POCUS: Point-of-Care Tips for Point-of-Care Ultrasound*, 1st edition.  
Copyright © McGraw-Hill Education. All rights reserved.

## Linear transducer vessel check

Video 05-02: Vessel check with linear transducer

Changing to the linear transducer allows a much higher resolution evaluation of the soft tissue and peritoneum. This video shows the abdominal muscles, and clearly demonstrates a lack of vascular structures in the intended needle path.



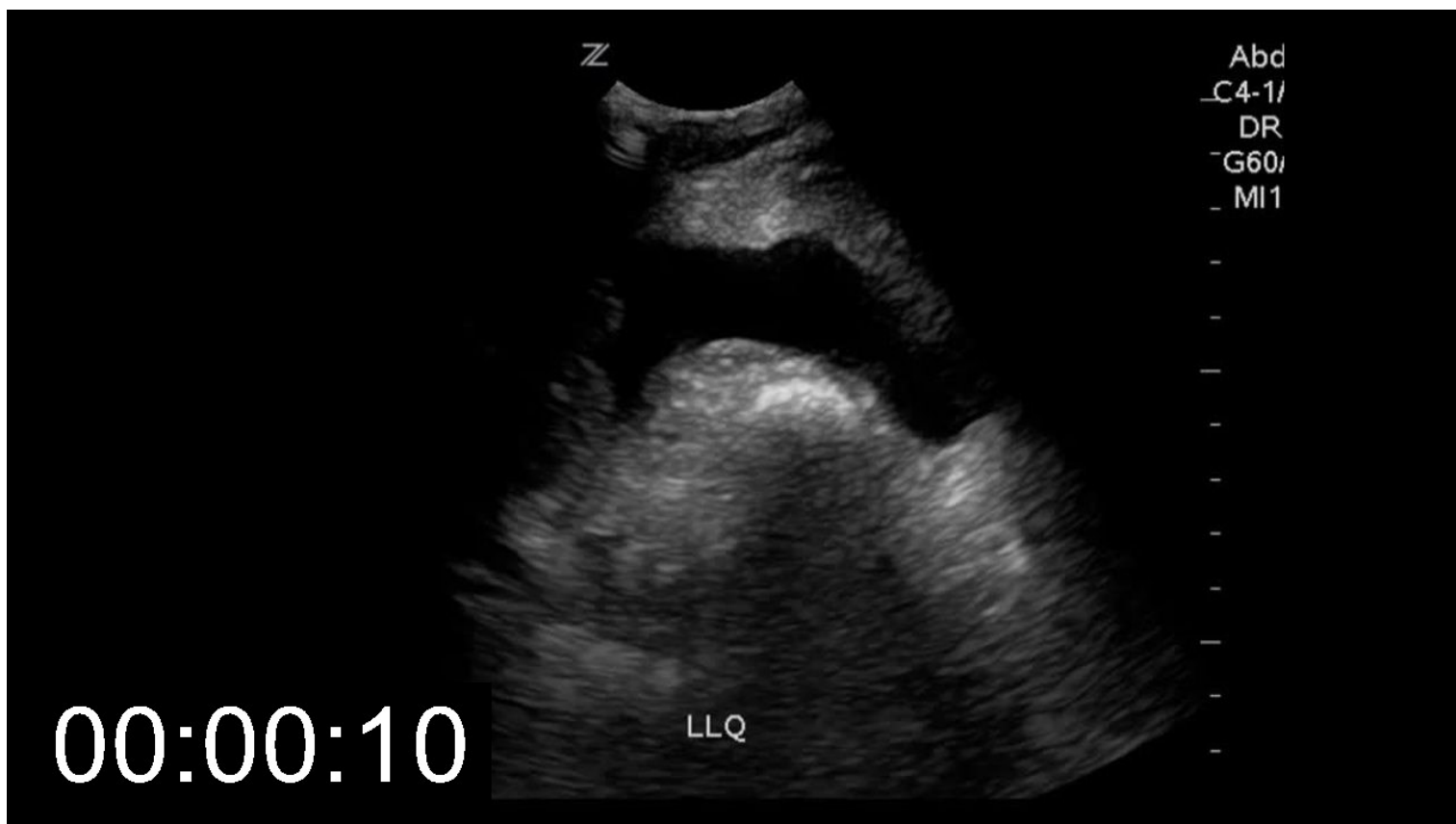
[Play Video](#)

## Real-time guidance of needle longitudinally

Only if necessary for a small pocket

## Video 05-03: Real time needle guidance

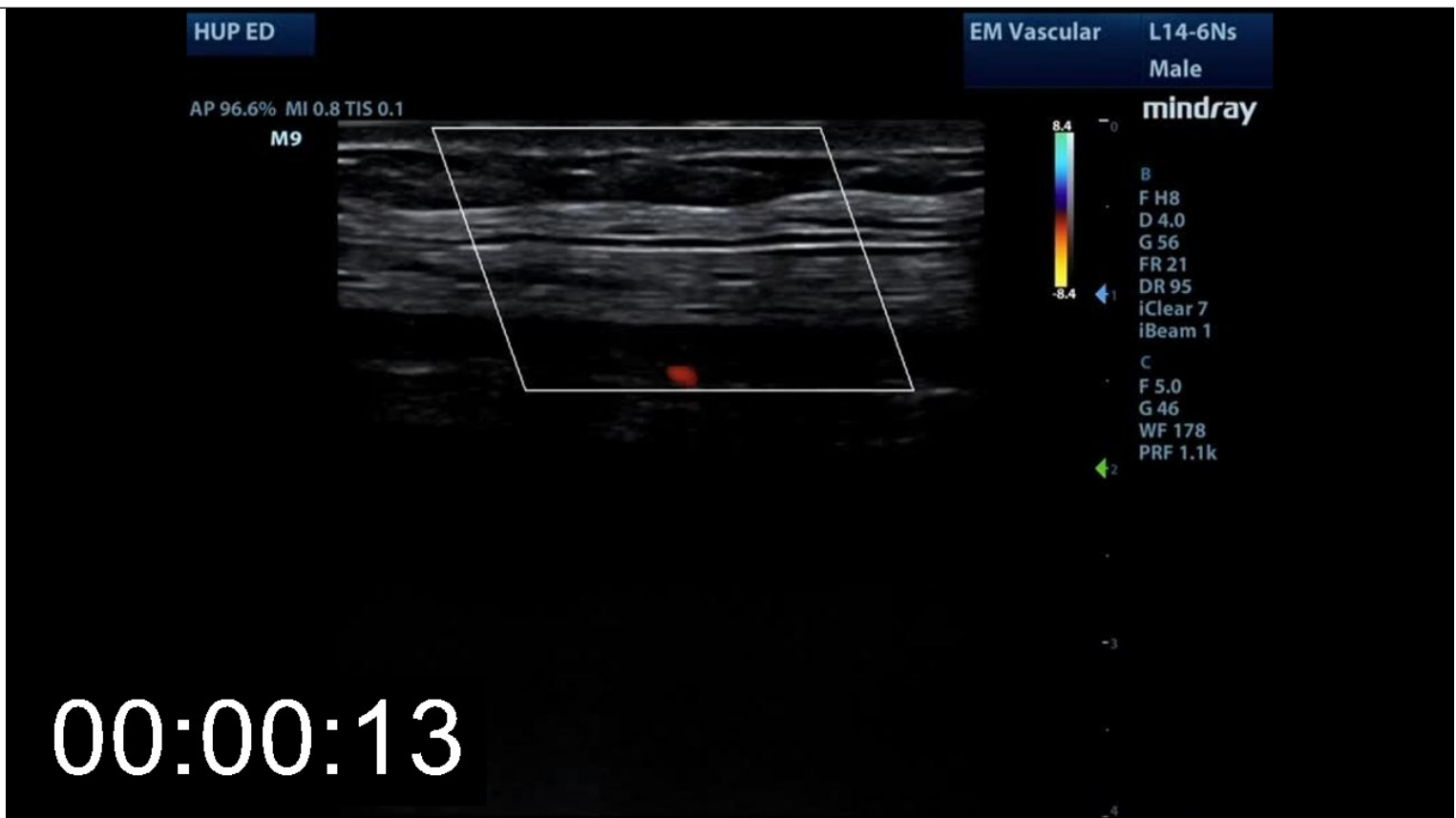Using the longitudinal approach, the needle can be seen penetrating the peritoneum and being guided into the free peritoneal fluid in this clip. Using this technique allows much more confidence when accessing a small pocket of fluid

[Play Video](#)**Linear transducer vessel check, color Doppler**

This is an advanced technique, no vessels seen

## Video 05-04: Vessel check with color Doppler

The color doppler and linear transducer reveal a small vessel in the subcutaneous space initially chosen for this procedure. The operator then quickly scans inferiorly and identifies an alternative site with no visible vessels.

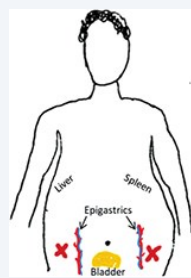


[Play Video](#)

## ACQUISITION TIPS

- This procedure can be done either with ultrasound identification of a safe pocket followed by blind needle insertion, or under real-time guidance using a technique similar to vascular access (see [Chapter 3](#)).
- Try sitting the patient up slightly and rotating to move bowel out of the way. Scan in both short and long axis.
- Safe pockets are frequently in the RLQ and LLQ. The midline is described as a reasonable target, but a full bladder increases the risk. If that target is chosen, ask the patient to void, check the location and size of the bladder with ultrasound to ensure absence of retention, and place a urinary catheter if necessary.

Things to avoid: liver, spleen, epigastric vessels, bowel, and bladder.



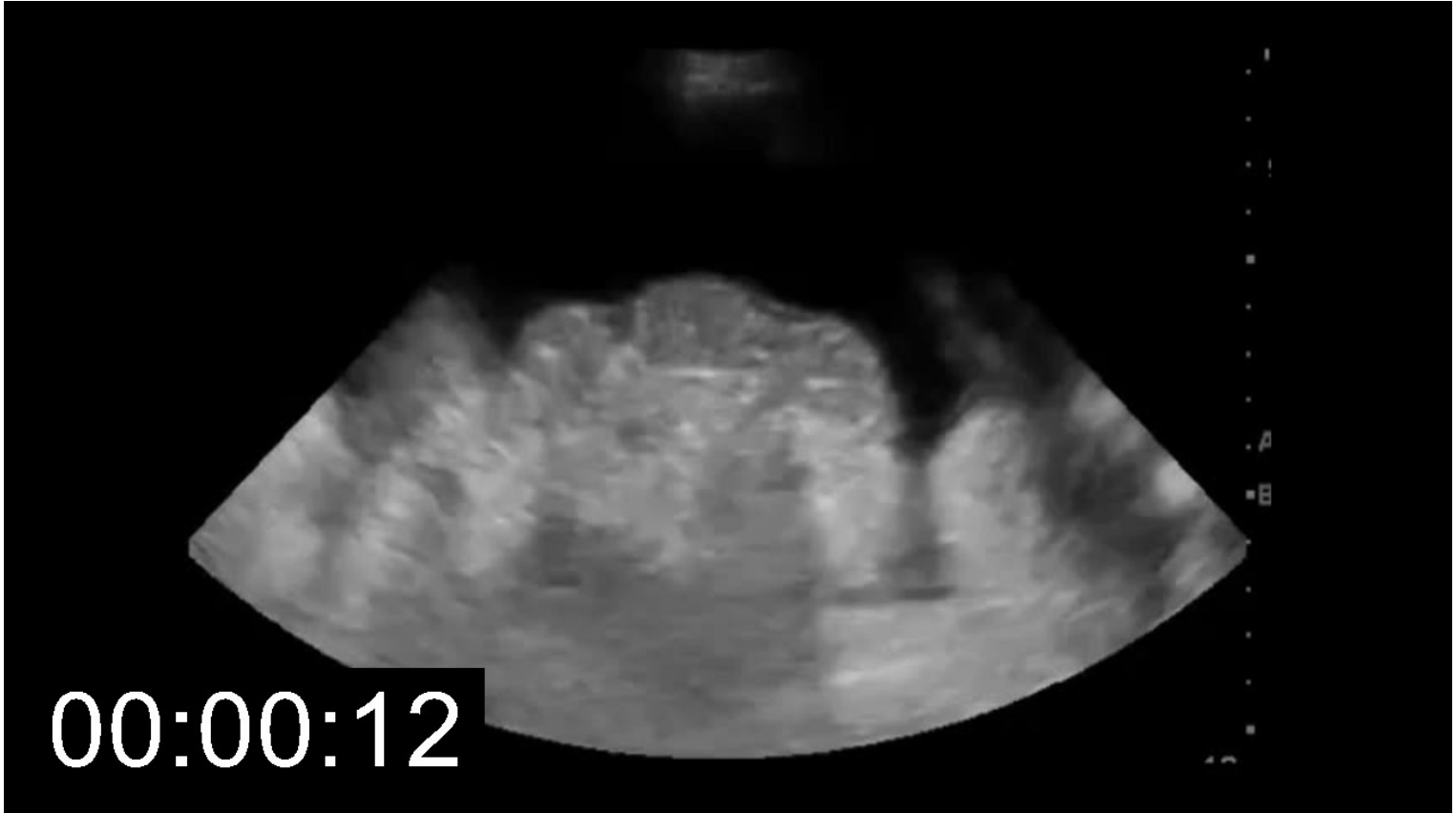
Remember that a bladder is a fluid-filled structure with round edges, while free fluid in the abdomen will make acute angles.

- Initially scan with the phased-array or curvilinear probe; once a safe place is identified mark it with a pen cap or skin marker.
- Adjust your gain to make sure fluid looks black.
- Measure the depth of the soft tissue (to the fluid) and from soft tissue to bowel.
- Check the marked space with a linear probe to make sure there are no hidden vessels, especially deep to the abdominal wall.
- The probe should be held perpendicular to skin. If the angle of the needle does not perfectly match the angle of the probe, it can result in procedural errors.

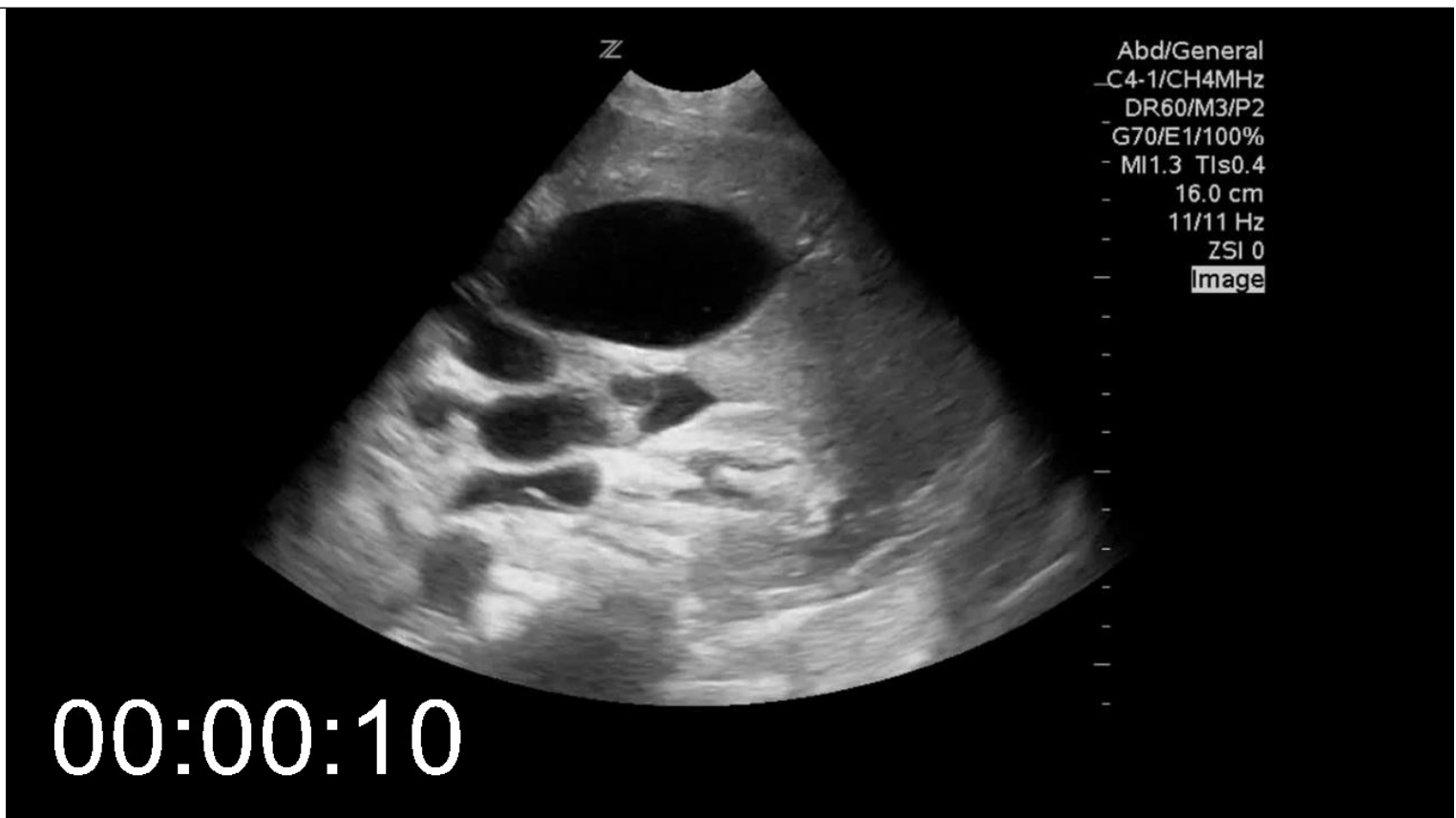- Do not allow patient to move between ultrasound and paracentesis.
- If bowel is dynamic, or if the procedure is high risk for other reasons (e.g., coagulopathy, small target), real-time ultrasound guidance should be considered.

**Video 05-05: Safe Pocket of Ascites**

This video demonstrates a pocket of ascitic fluid which would be safe for paracentesis. The soft tissue is at the top of the screen, and there is at least 3 cm of free fluid between the soft tissue and the cloud-like bowel. Peristalsis can be seen in the loops of bowel.

[Play Video](#)**Video 05-06: Free fluid compared to fluid in viscera**

The round structure in the center of the screen is a gallbladder. Outside of the gallbladder can be seen the acute angles of free fluid. This important characteristic allows distinction between fluid inside viscera (bowel, bladder, or gallbladder especially) and the free fluid in the peritoneum.



[Play Video](#)

## INTERPRETATION AND PITFALLS

- **Soft-tissue depth:** This depth lets you know when you should expect to aspirate fluid.
  - The peritoneum is highly innervated. Anesthetic can be administered under the skin and at the peritoneum under ultrasound guidance.
  - If the needle passes the measured depth without hitting fluid, the most common error is misalignment of the needle (not the same angle against the skin as the ultrasound was when evaluating for fluid).
  - The peritoneum can “tent” over the needle tip; a twisting motion can help pass a thickened or hardened peritoneum.
  - The needle should be at least 1 cm longer than the distance to the ascites.
- **Fluid depth:** This depth lets you know how much fluid you would have to pass through to hit bowel or other structures.
  - Should be at least 3 cm for a marked procedure.
  - If fluid depth is <3 cm, consider using real-time guidance.
  - Fan through a range of angles to ensure awareness of nearby structures.
  - Check for adherent bowel that is stuck to the abdominal wall.
- **A-lines:** Air artifact
  - Normally this is caused by bowel gas, but advanced practitioners can use it to evaluate for air below the diaphragm in the upright patient.
- **Loculations, septations, and fibrin:** Thin white lines within ascites which may impede fluid drainage. Usually seen in infection or malignancy.
- **Hepatomegaly and splenomegaly:** Viscera can extend deeply into the pelvis. Identify the inferior border of each before continuing with procedure.
- **Liquid stool in bowel:** Bowel loops containing liquid stool can be mistaken for a pocket of fluid.
  - Remember the “acute angles” of free fluid.

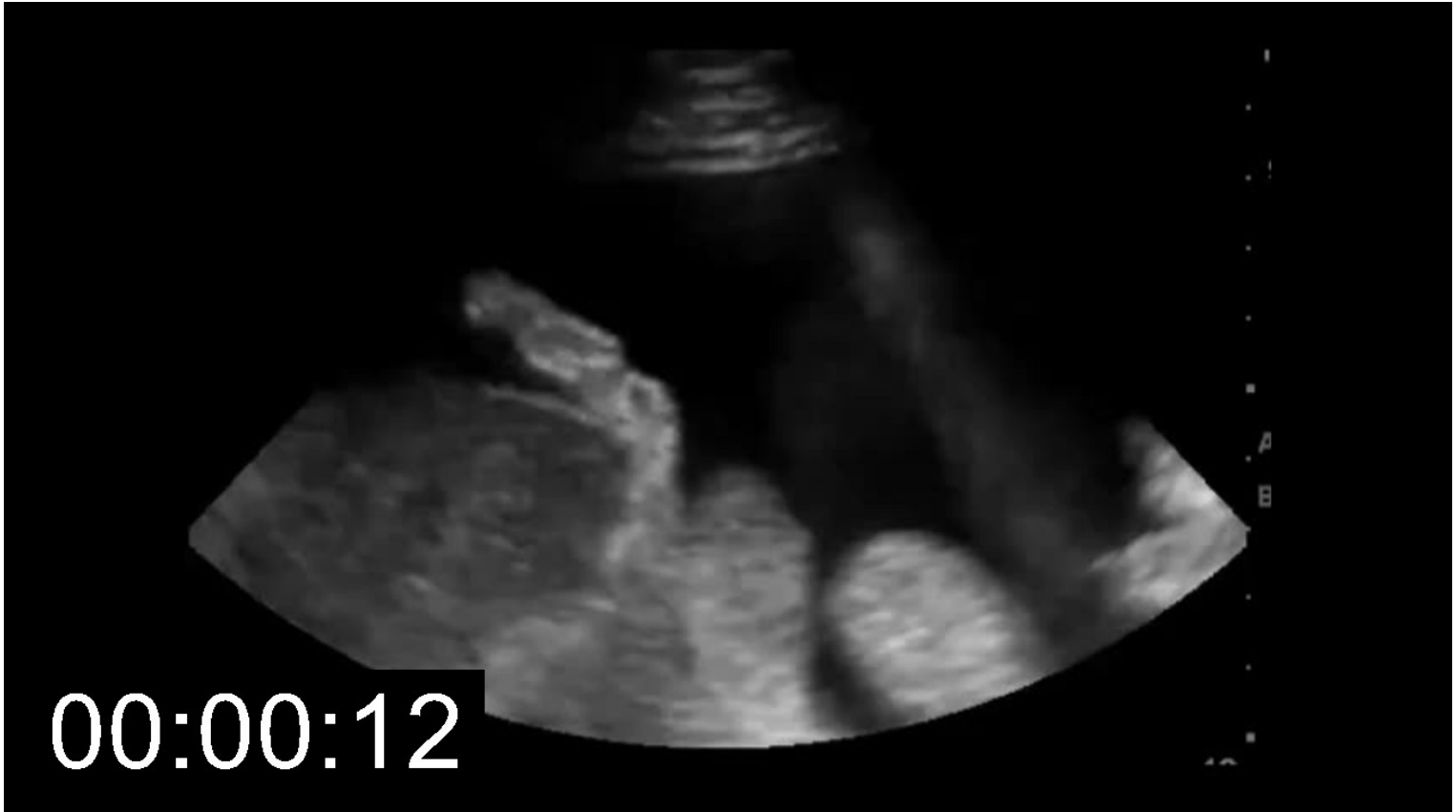

- Look for peristalsis and gas bubbles.
- **Full bladder/cysts: pancreatic pseudocysts, ovarian cyst, and the urinary bladder can be mistaken for ascitic fluid.**
  - Identify the “acute angles” of free fluid.
  - Look out for the rounded border of fluid-filled anatomic structures.

## EXAMPLES OF PATHOLOGY

Video 05-07: Ascites with liver tip in view

While this pocket is of sufficient depth for a procedure, the left side of the screen demonstrates a liver tip that is close to the intended path of the needle. If seen, it is best to slide the probe inferiorly in order to identify a region without liver in the field.

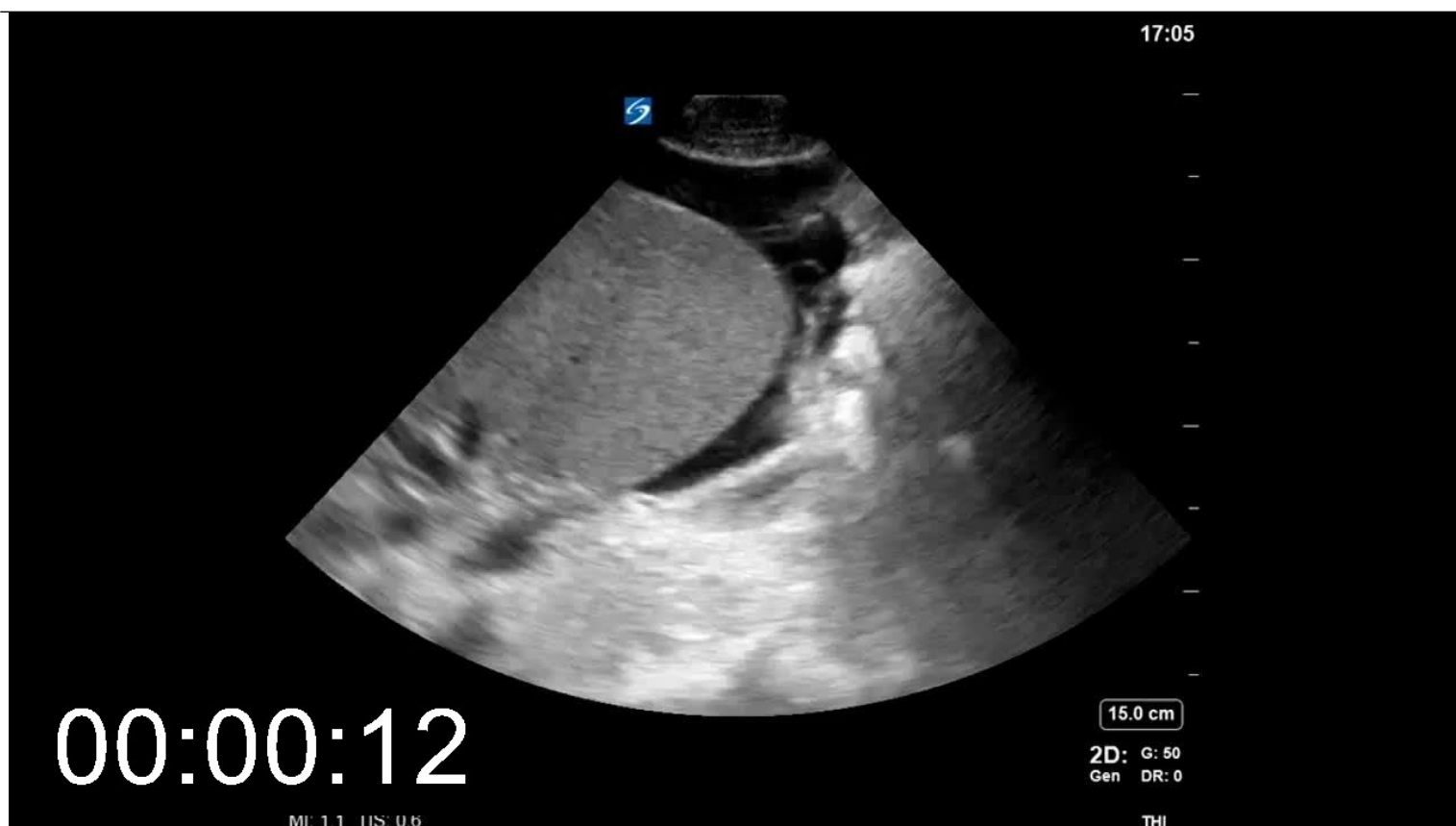


[Play Video](#)

Video 05-08: Ascites with spleen tip in view

In this patient with massive splenomegaly the left lower quadrant is not a safe target for paracentesis.

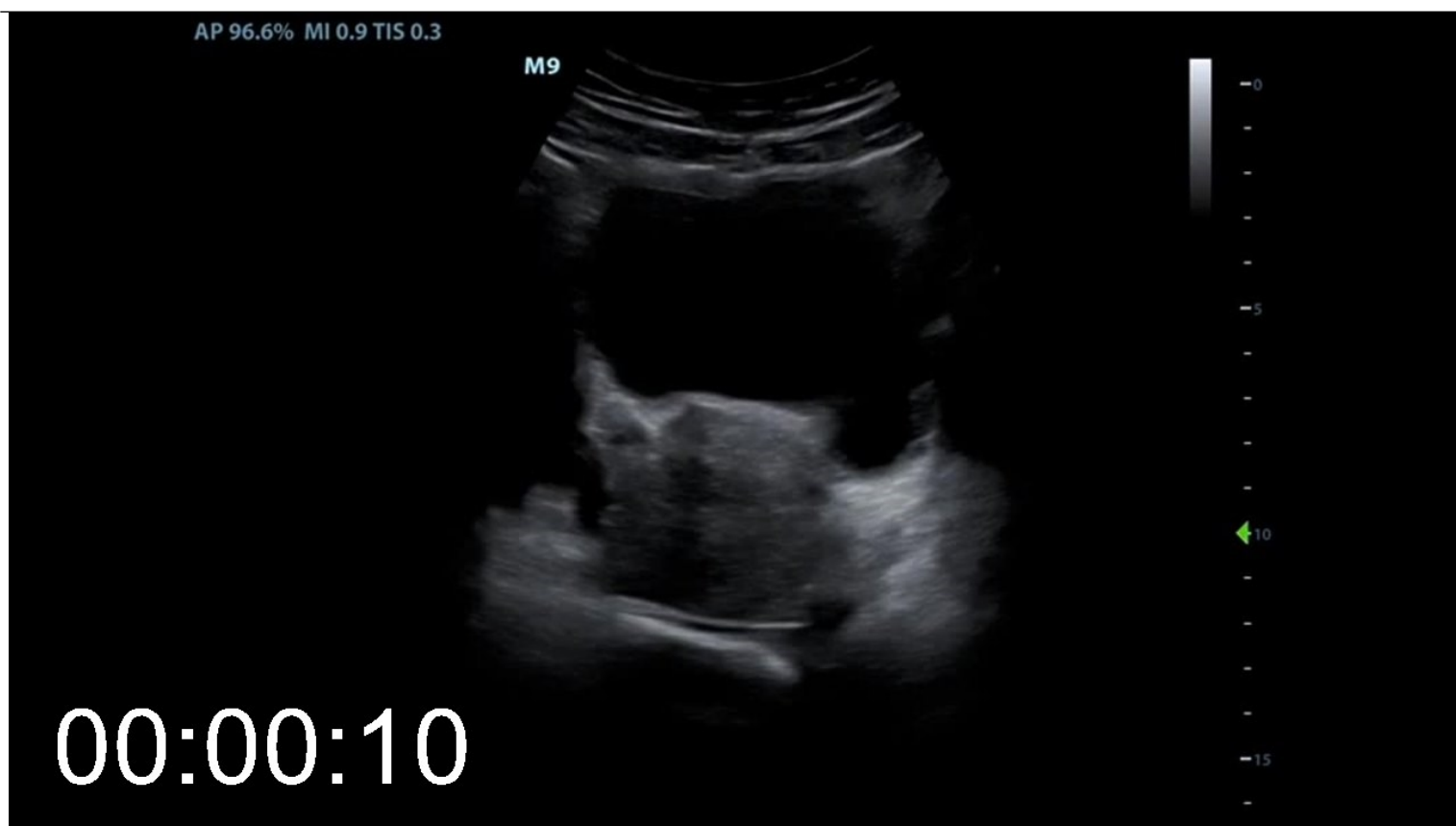



[Play Video](#)

Video 05-09: Full bladder

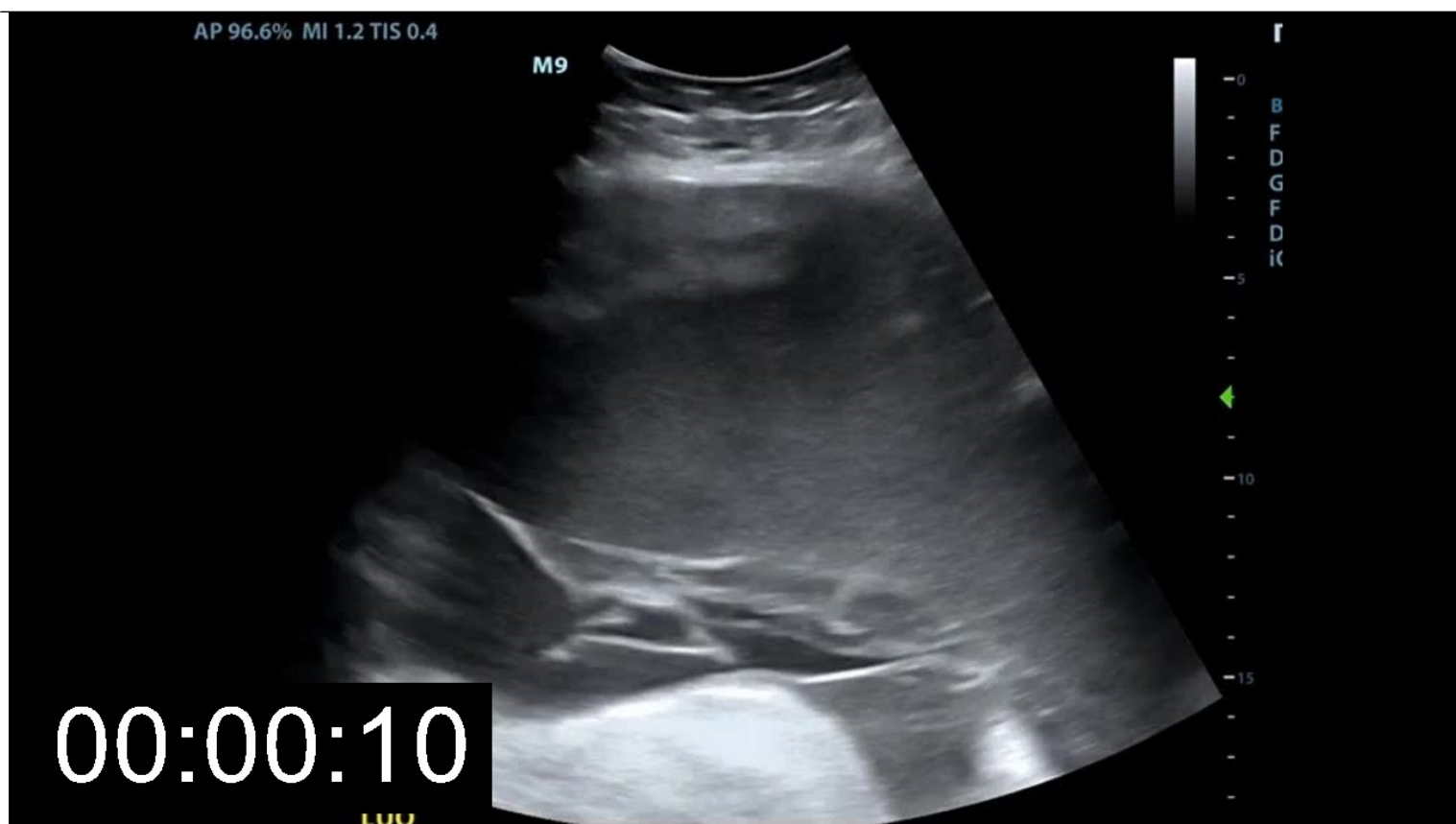It is important not to mistake a bladder full of urine for free fluid in the abdomen. This video demonstrates the rounded corners of a bladder seen in the transverse view as well as the uterus deep to the bladder with no free fluid in the pouch of Douglas.



[Play Video](#)

Video 05-10: Loculated ascites

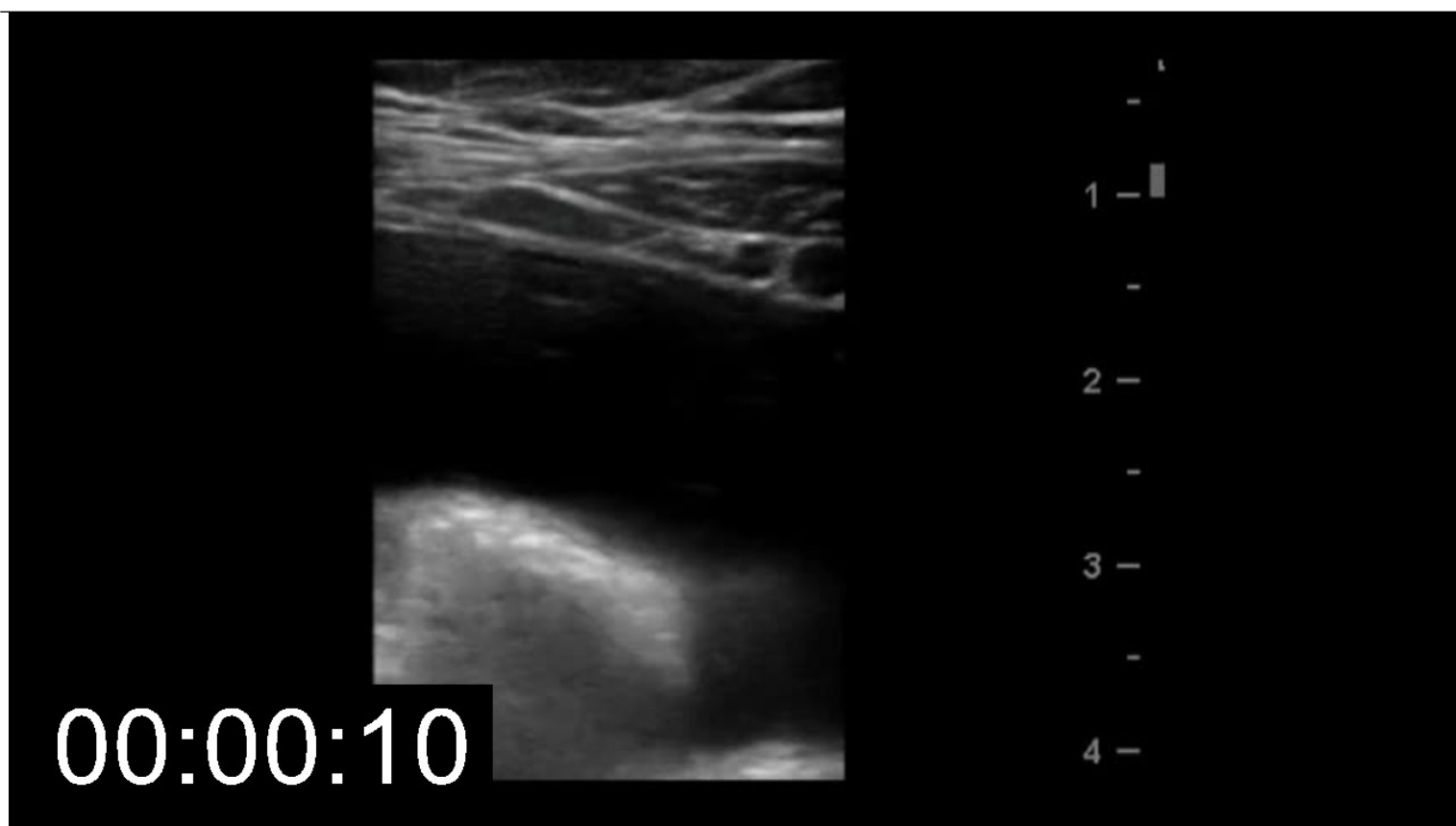
This view of the left side of the abdomen demonstrates free fluid deep to the spleen. While this is definitely not accessible by a needle via this approach, it is also important to note the thin echogenic lines throughout the fluid that are visual representations of septations, suggesting an inflammatory or hemorrhagic etiology for the fluid.



[Play Video](#)

Video 05-11: Epigastric vessels

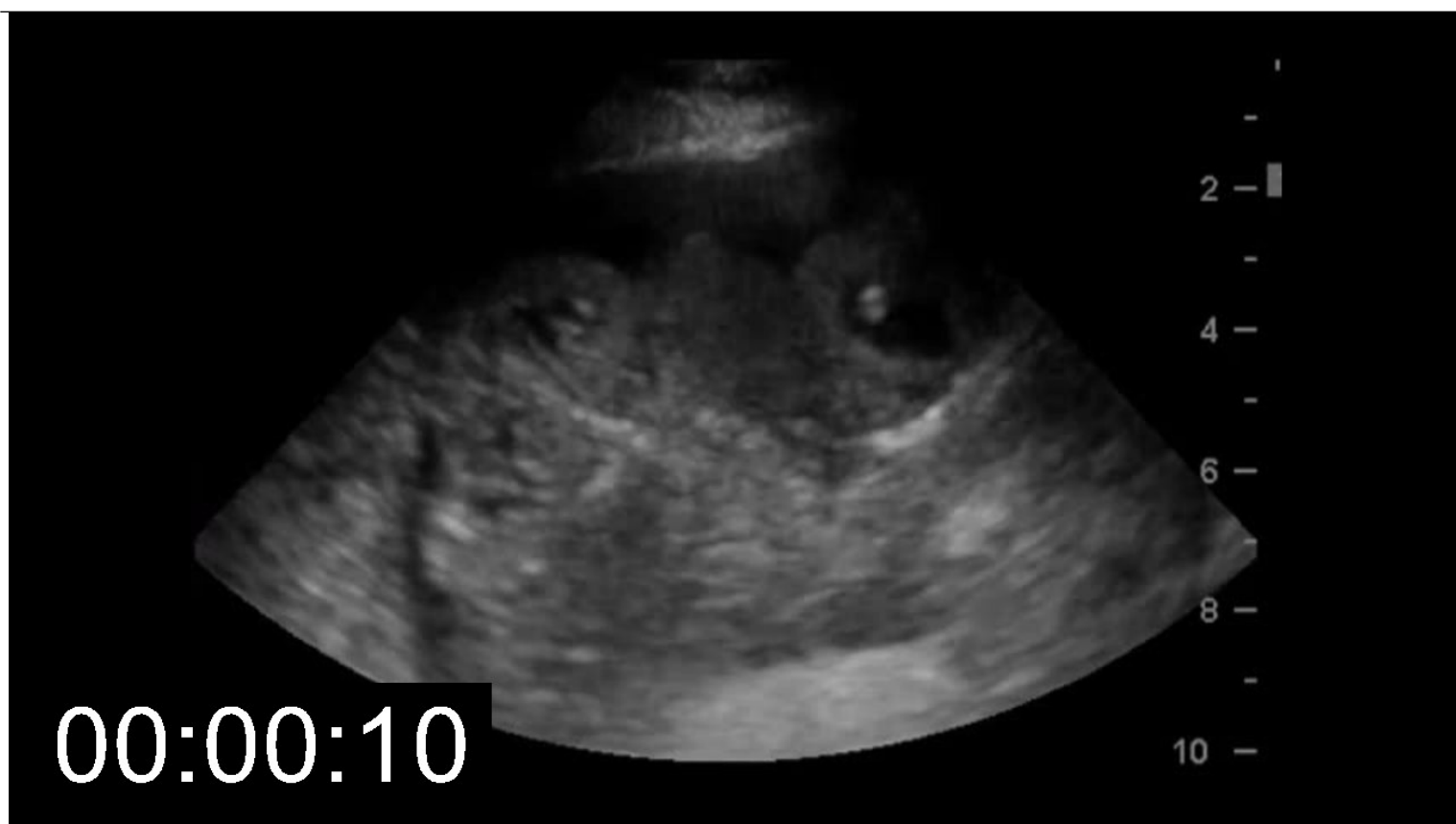This video was captured using the linear transducer. The ascitic fluid is deep to the 1.5 cm of soft tissue, with bowel at the bottom of the screen. The right of the screen, however, demonstrates 2 round vessels just deep to the muscle belly. These are epigastrics and must be strictly avoided when planning a path for paracentesis.



[Play Video](#)

Video 05-12: Shallow ascites with visible stool

This video demonstrates a pocket of peritoneal fluid that is only about a centimeter in depth below the soft tissue. Inside the round bowel structures can be seen anechoic fluid which is not free in the abdomen, but in this case is liquid stool inspired by [lactulose](#) administration. This shallow pocket should probably only be accessed under real time ultrasound guidance.



[Play Video](#)